

**KUB**

■ **K-Kidneys**

■ **U-Ureter**

■ **B-Bladder**

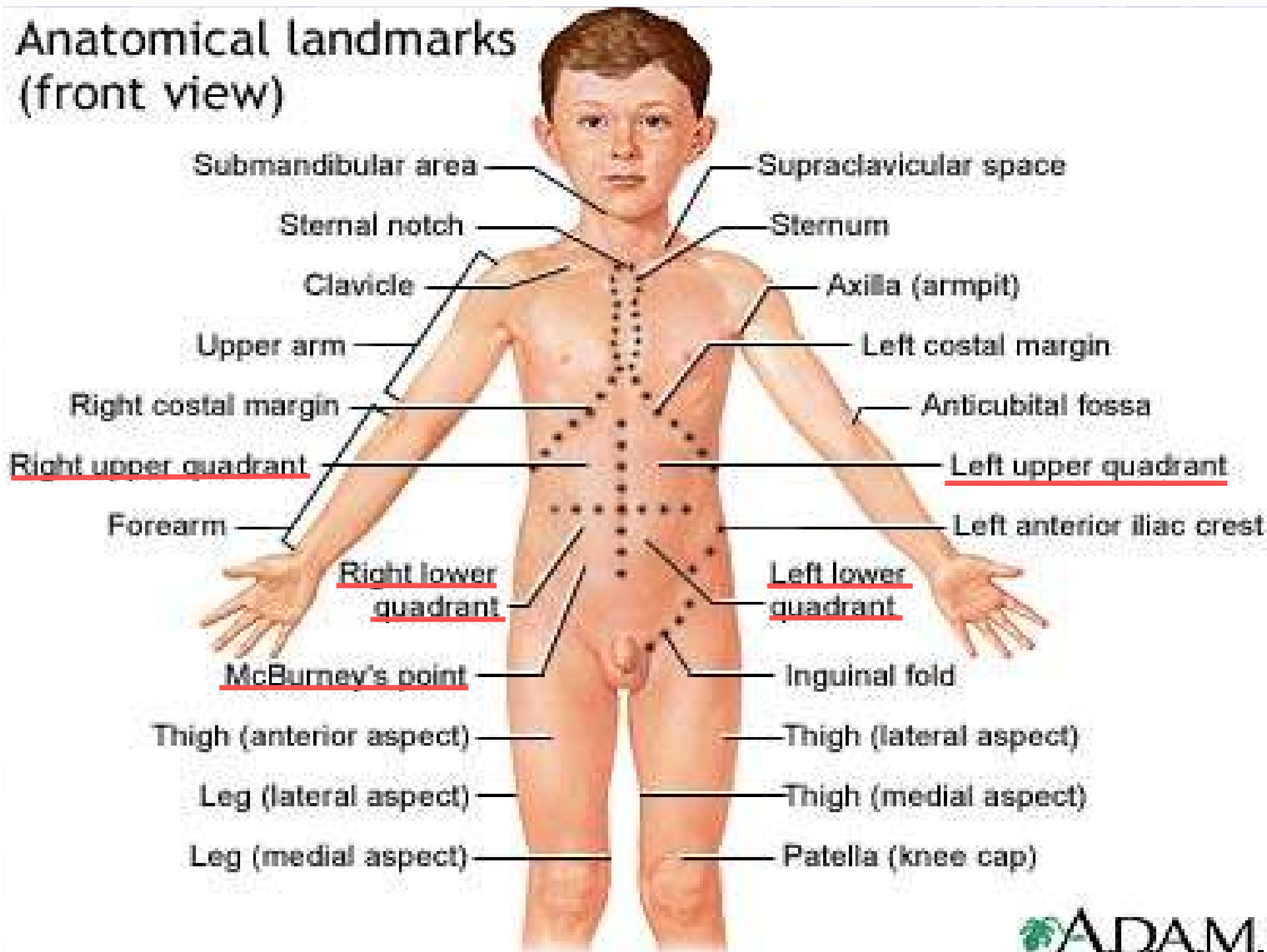
# 第一步

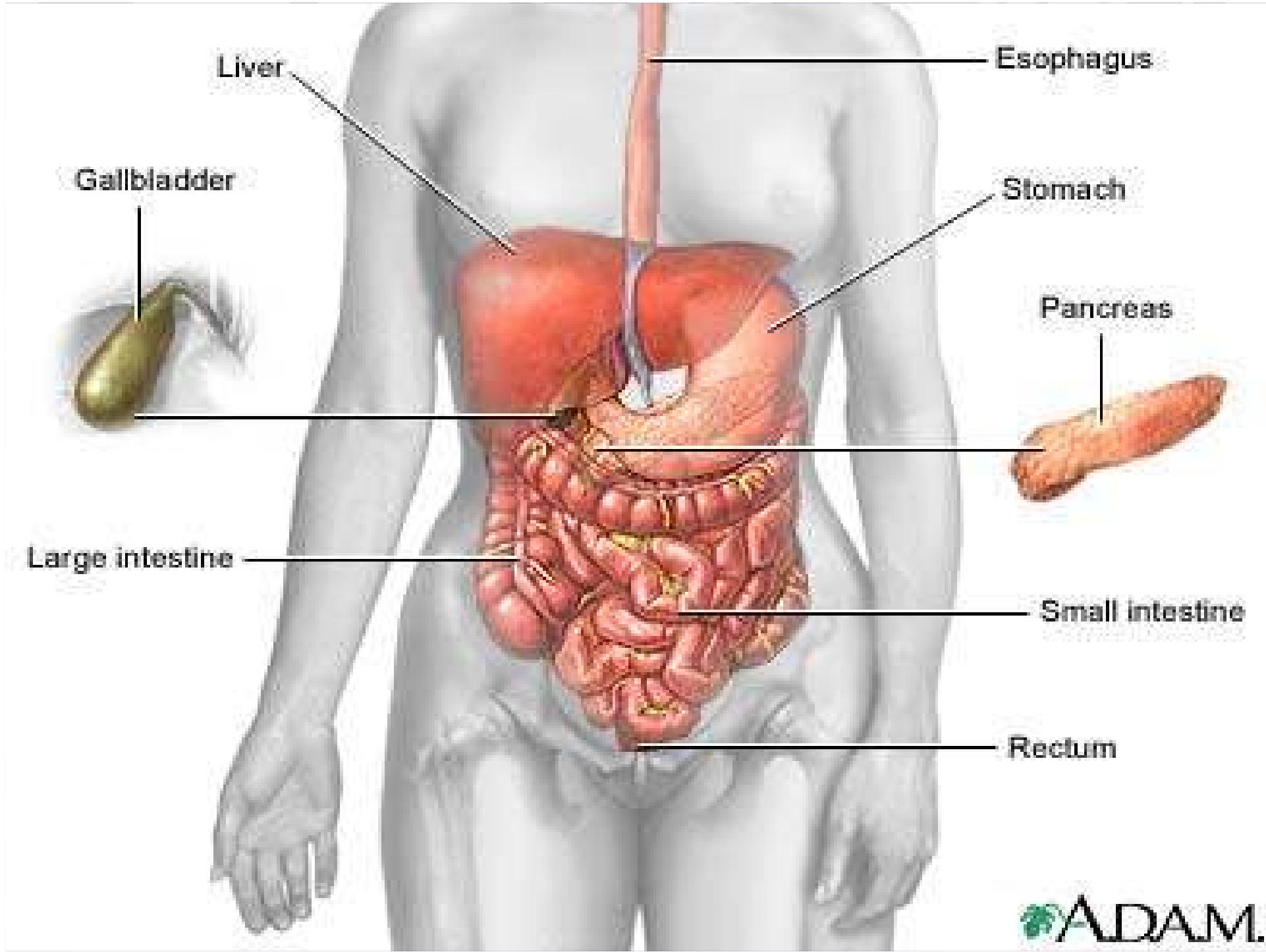
- 身份辨識最重要
  - wrong patient , right diagnosis
- AP film: supine
  - Standing KUB? Decubitus?

# 醫學英文

- 胃：stomach
- 腸：intestine, bowel
- 肝：liver
- 膽：Gallbladder
- 胰：pancreas
- 脾：spleen
- 腎：kidney
- 腎上腺：adrenal gland
- 輸尿管：ureter
- 膀胱：urinary bladder

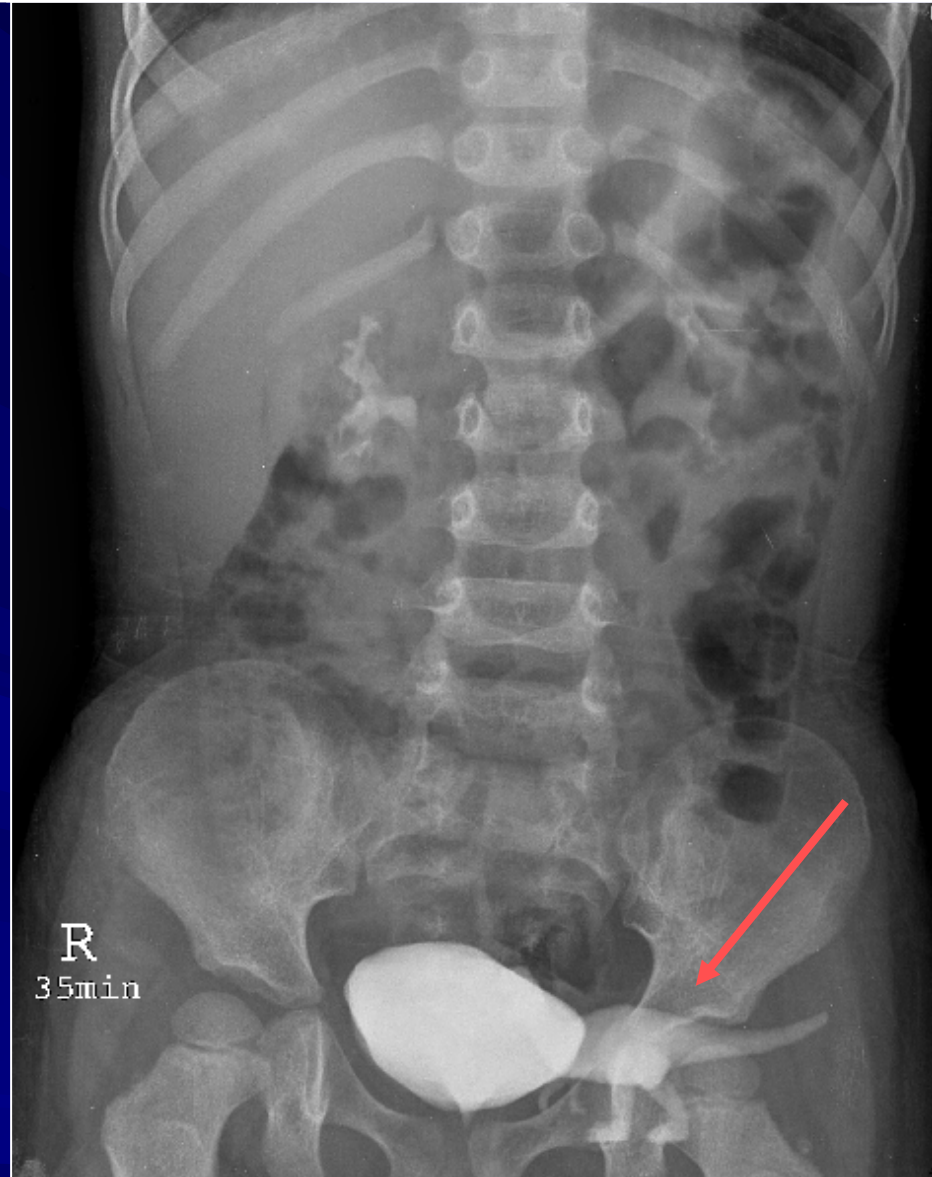
# Anatomical landmarks (front view)



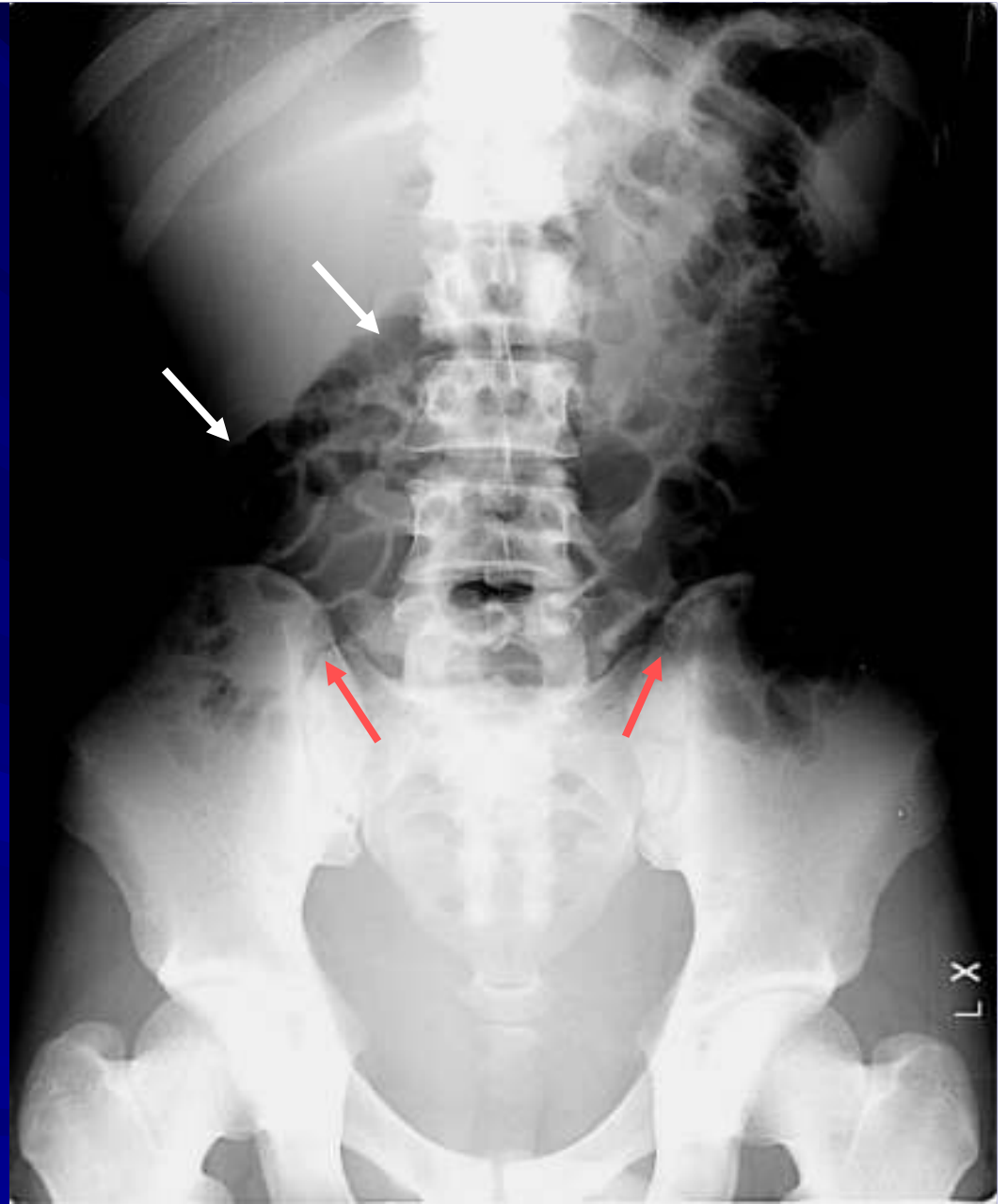
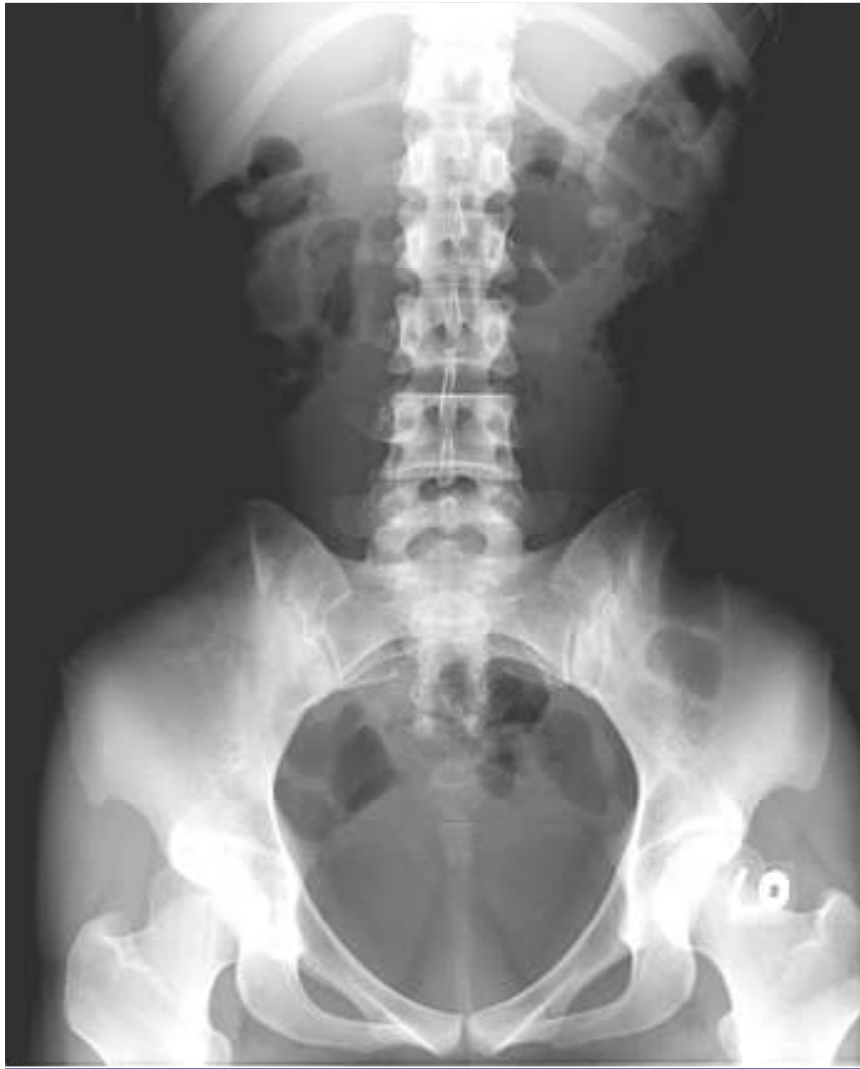

# 看什麼？

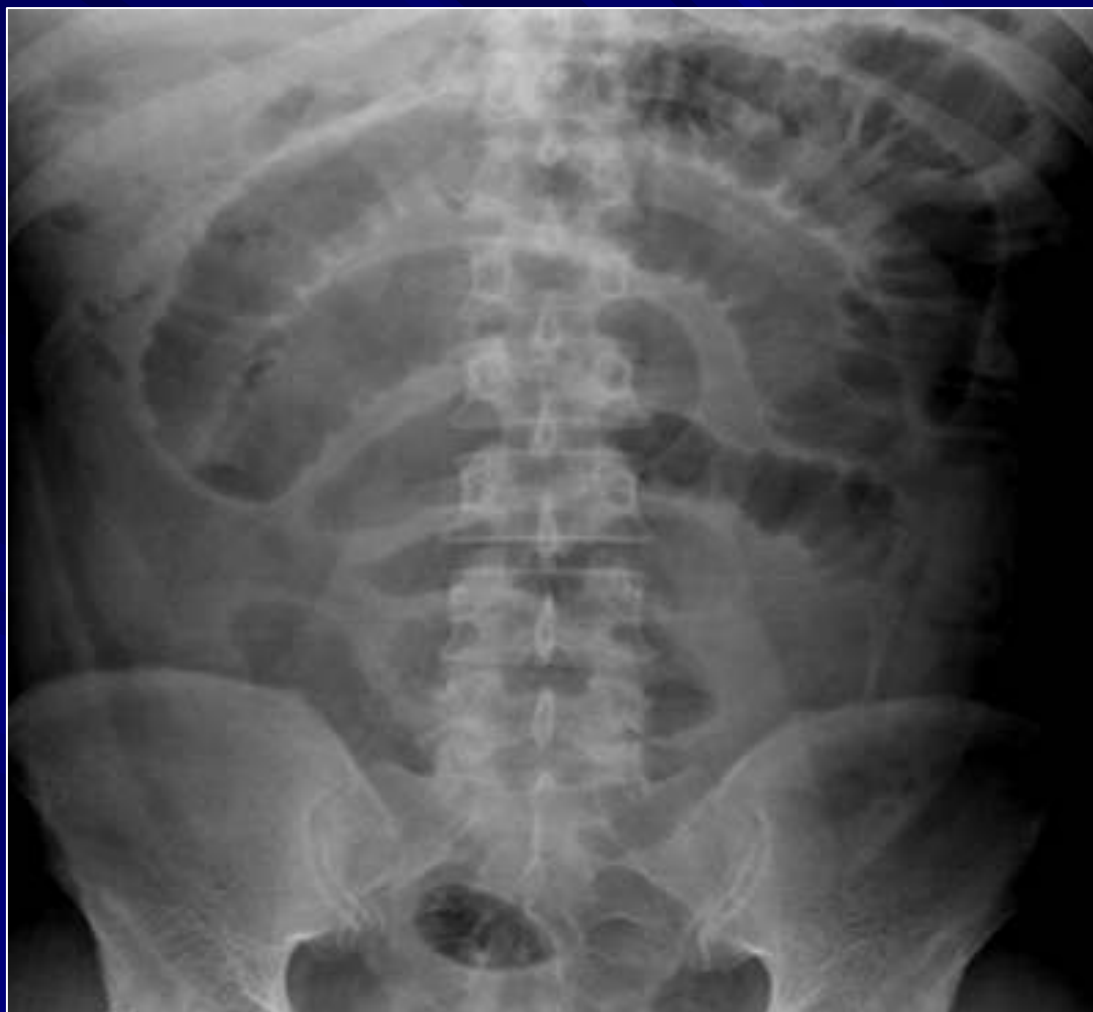- 灰的：
  - 器官：liver, spleen, kidney
    - 右邊kidney 比左邊低一點
  - Psoas muscle 邊緣：不清楚要考慮後腹腔有問題
- 黑的：空氣
  - 腸子裏面的空氣
  - 腸子外面的空氣：胃穿孔？
- 白的：骨頭、鈣化、異物



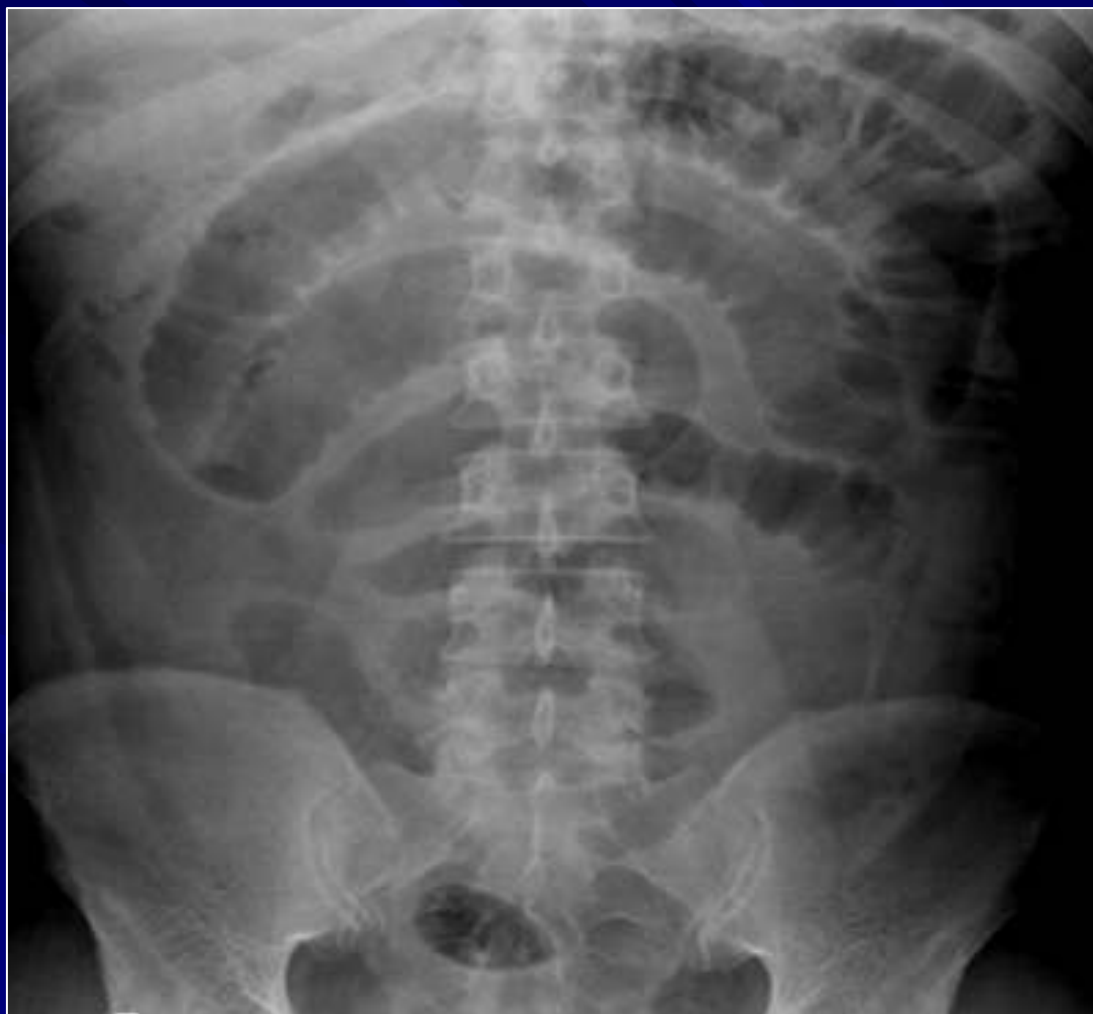當然，去除身上異物是很重要的



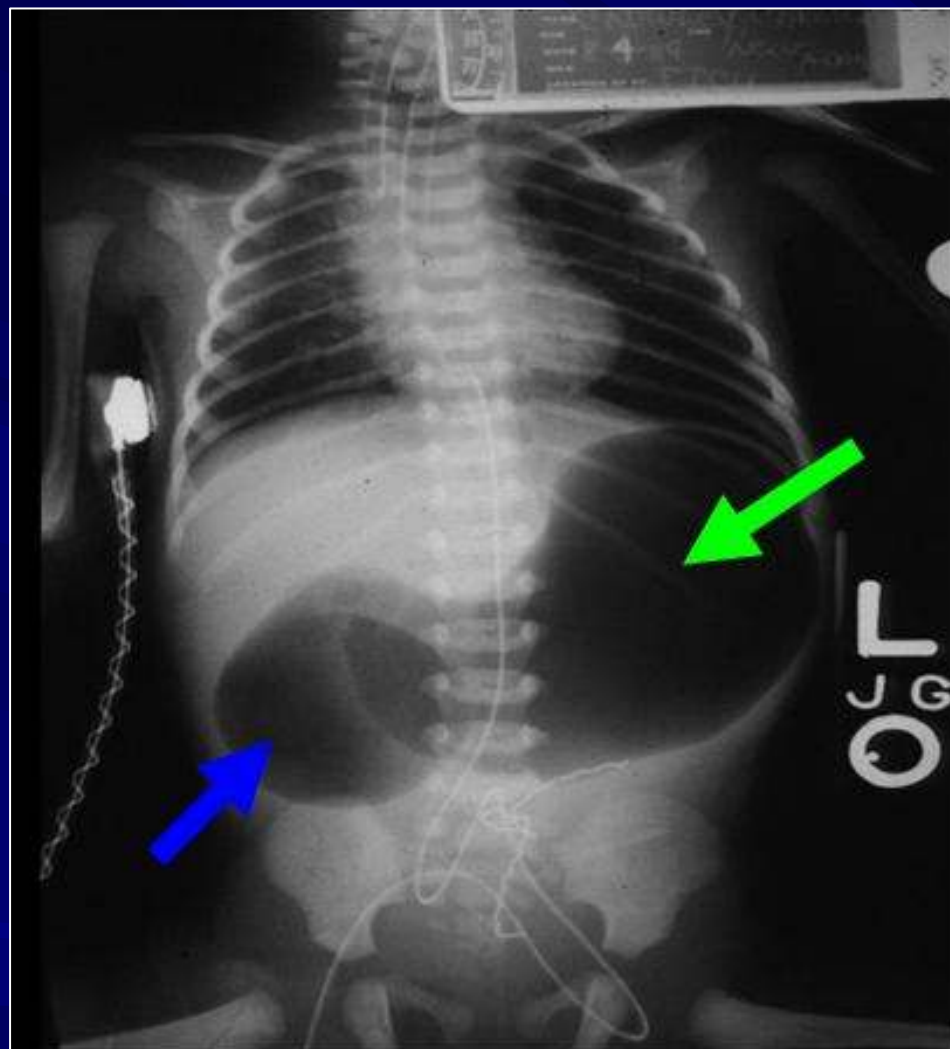
黑的是氣體



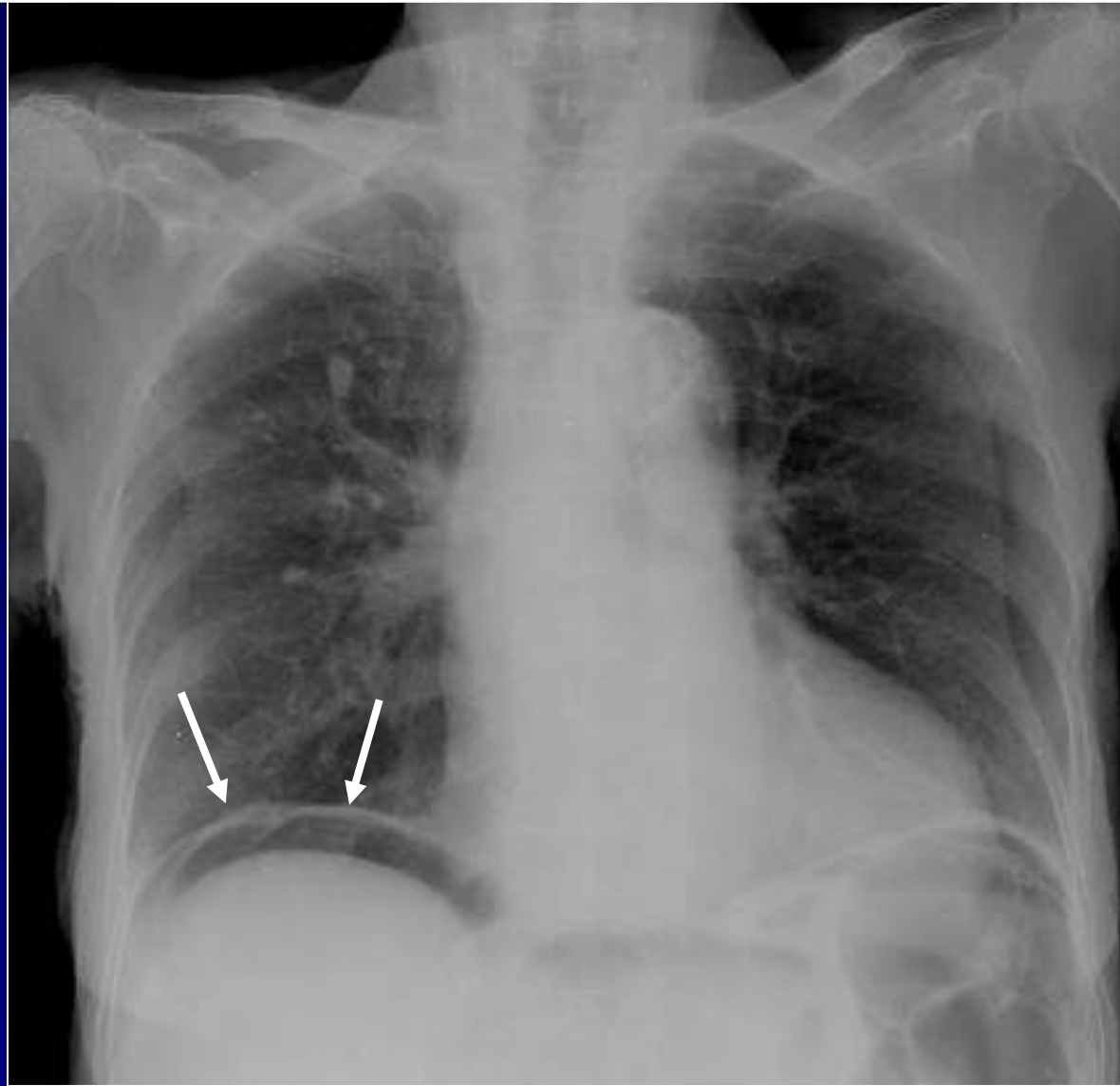
這個腸子那裏不對？



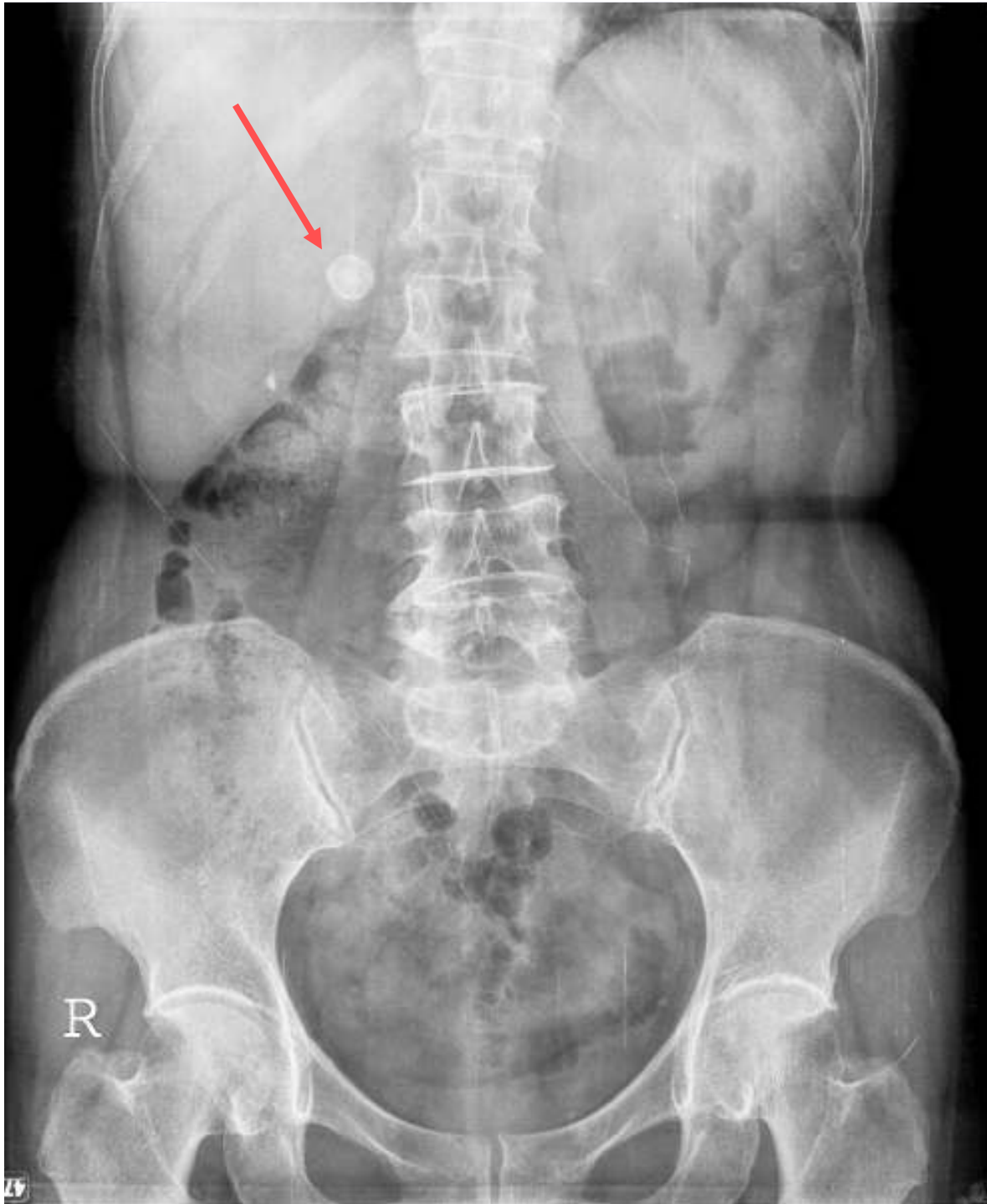
小腸太粗了：腸阻塞，腸子  
不動



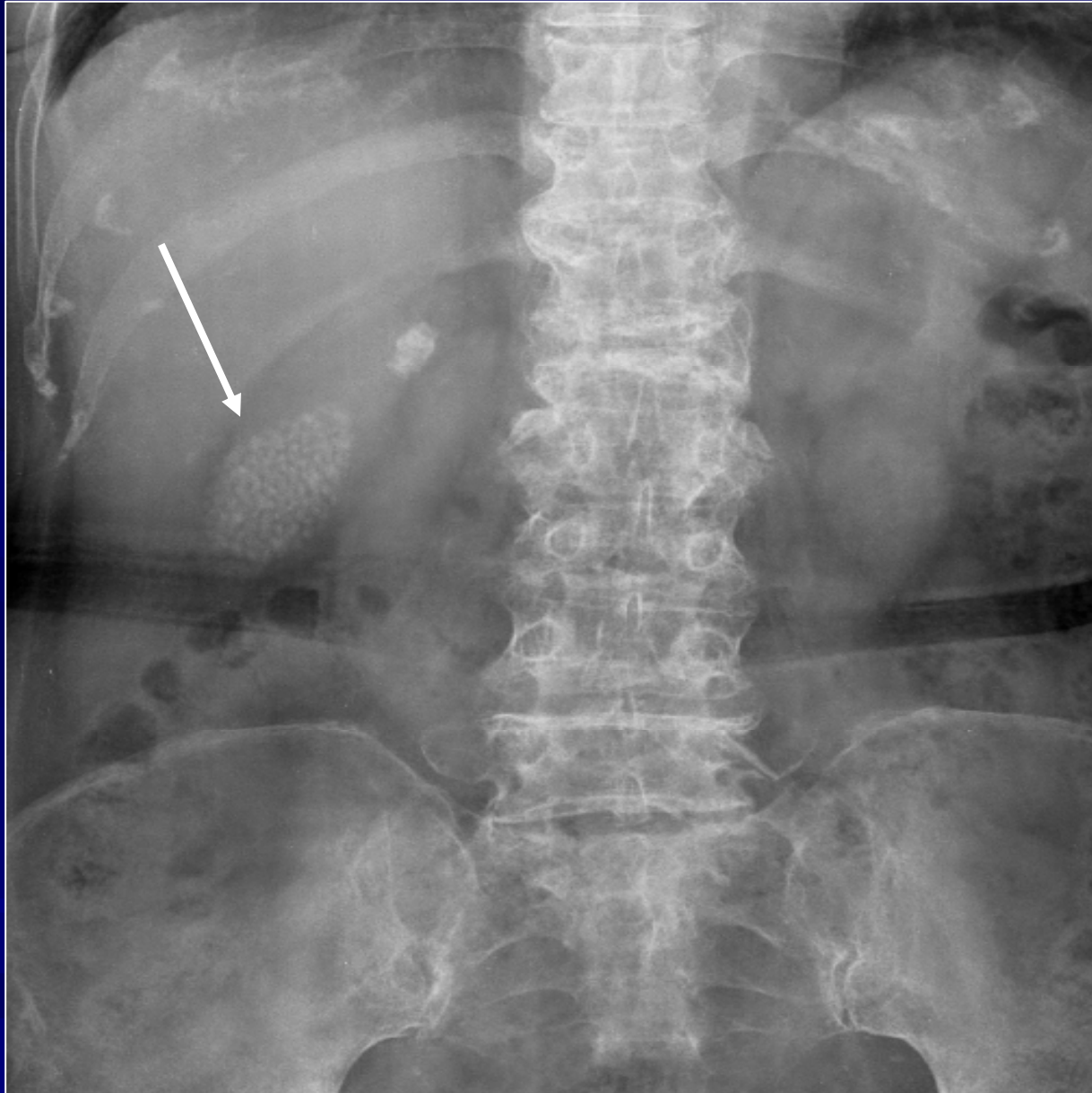
新生兒，  
猜猜看那  
裏阻塞？



胃穿孔，你一定會

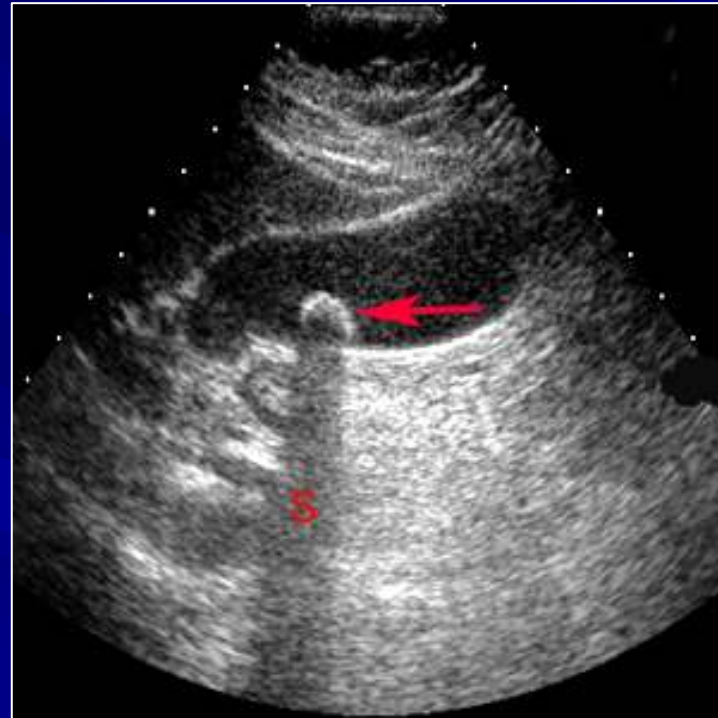
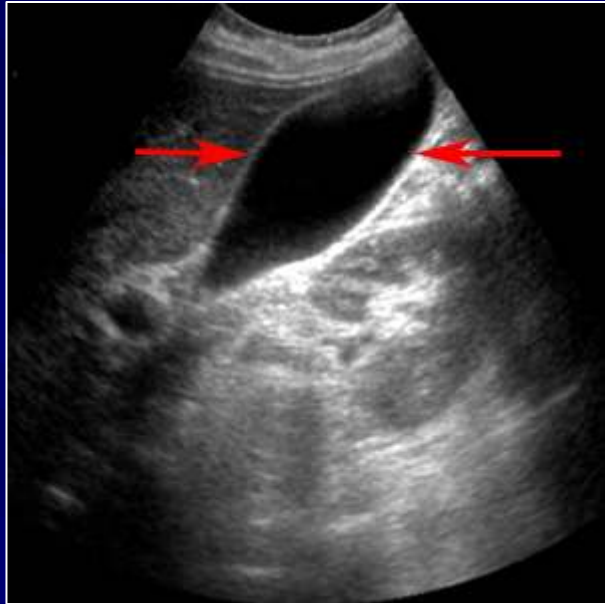


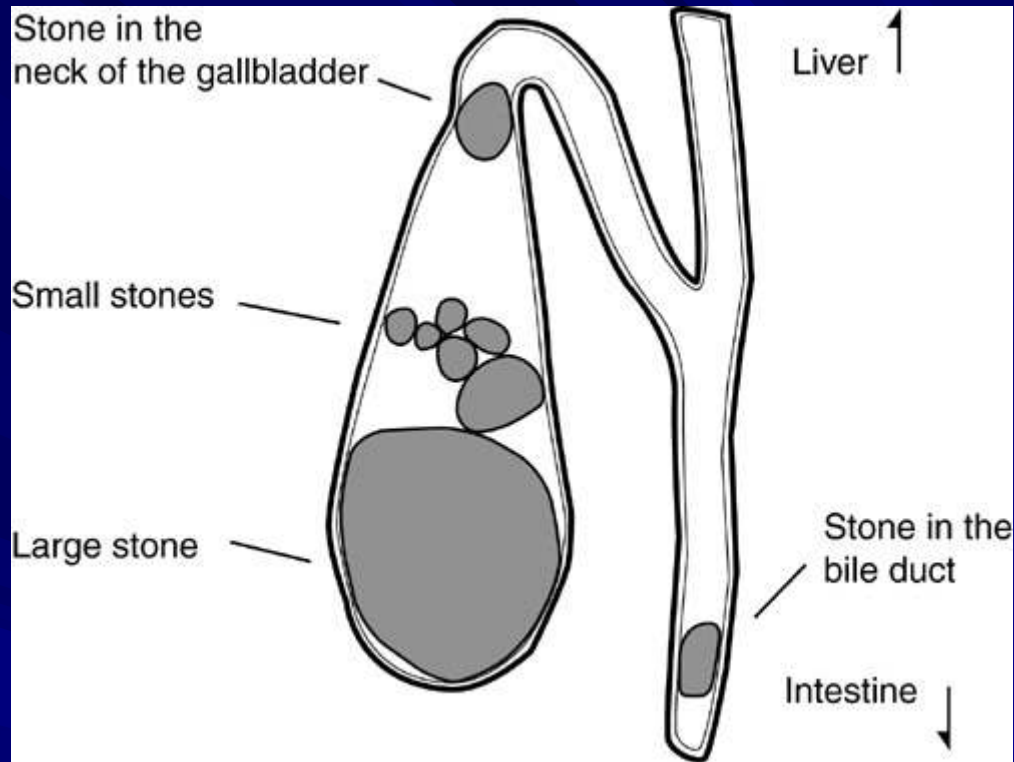
# 膽結石



膽結石也有長的像砂子的

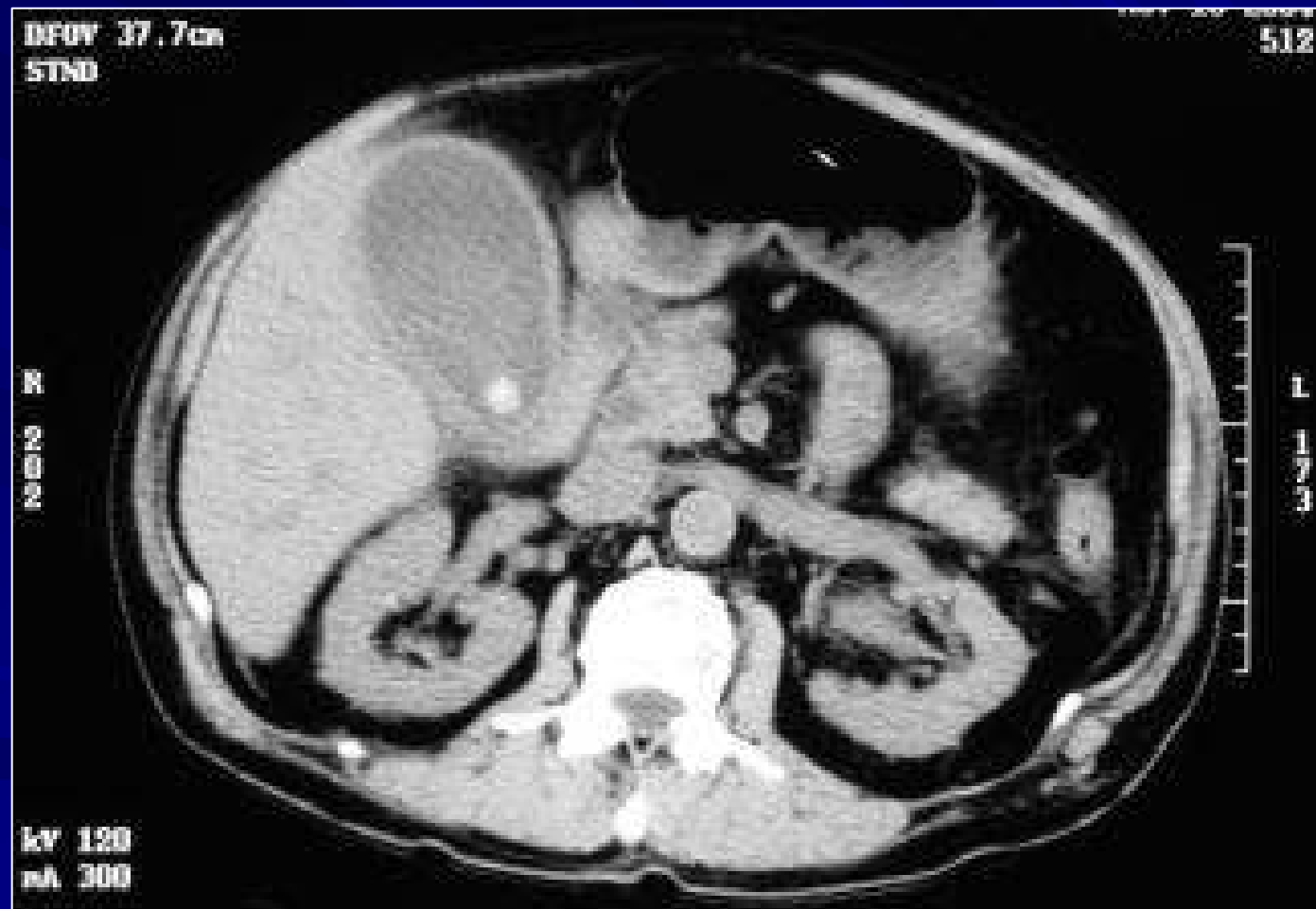# 同場加演

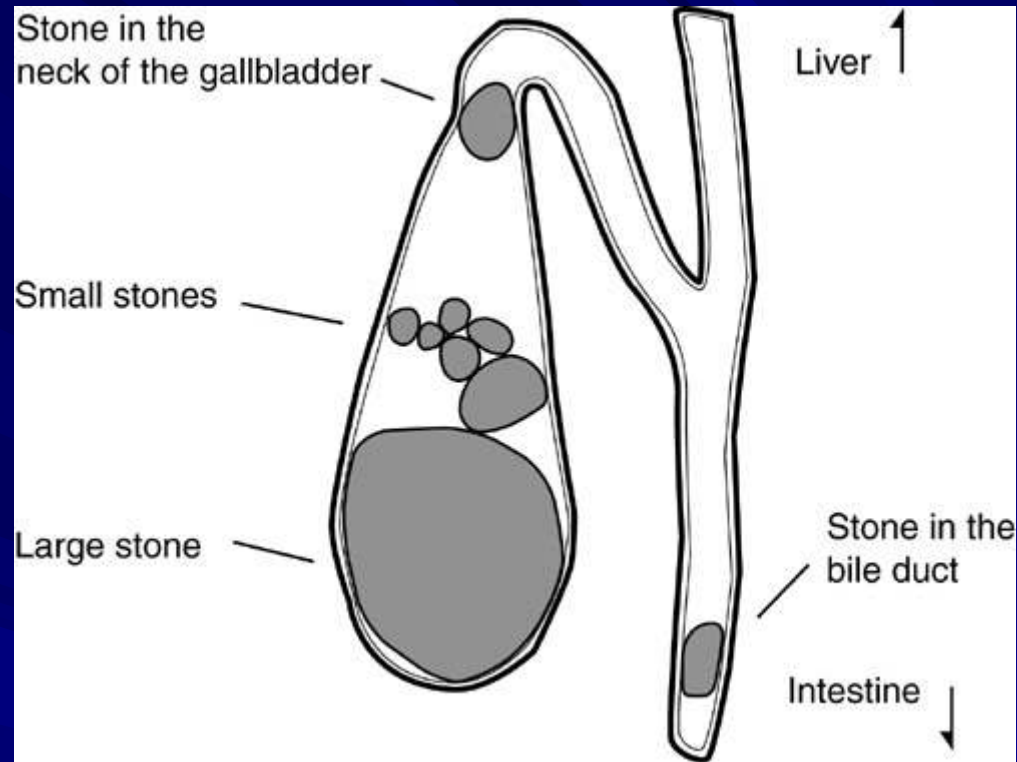




小心，膽結石堵到出口會造成膽囊炎

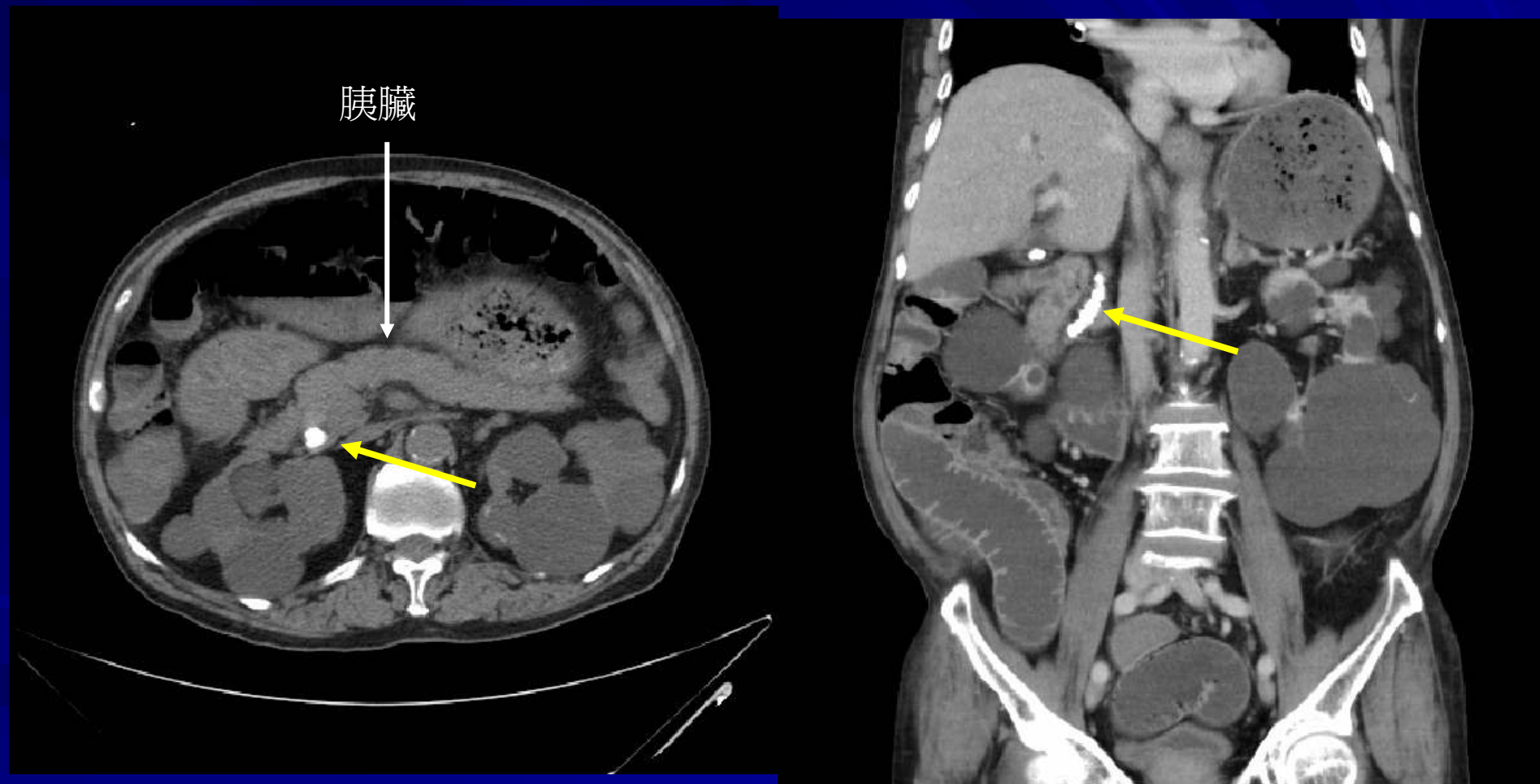
# 同場加演：膽結石、膽囊炎

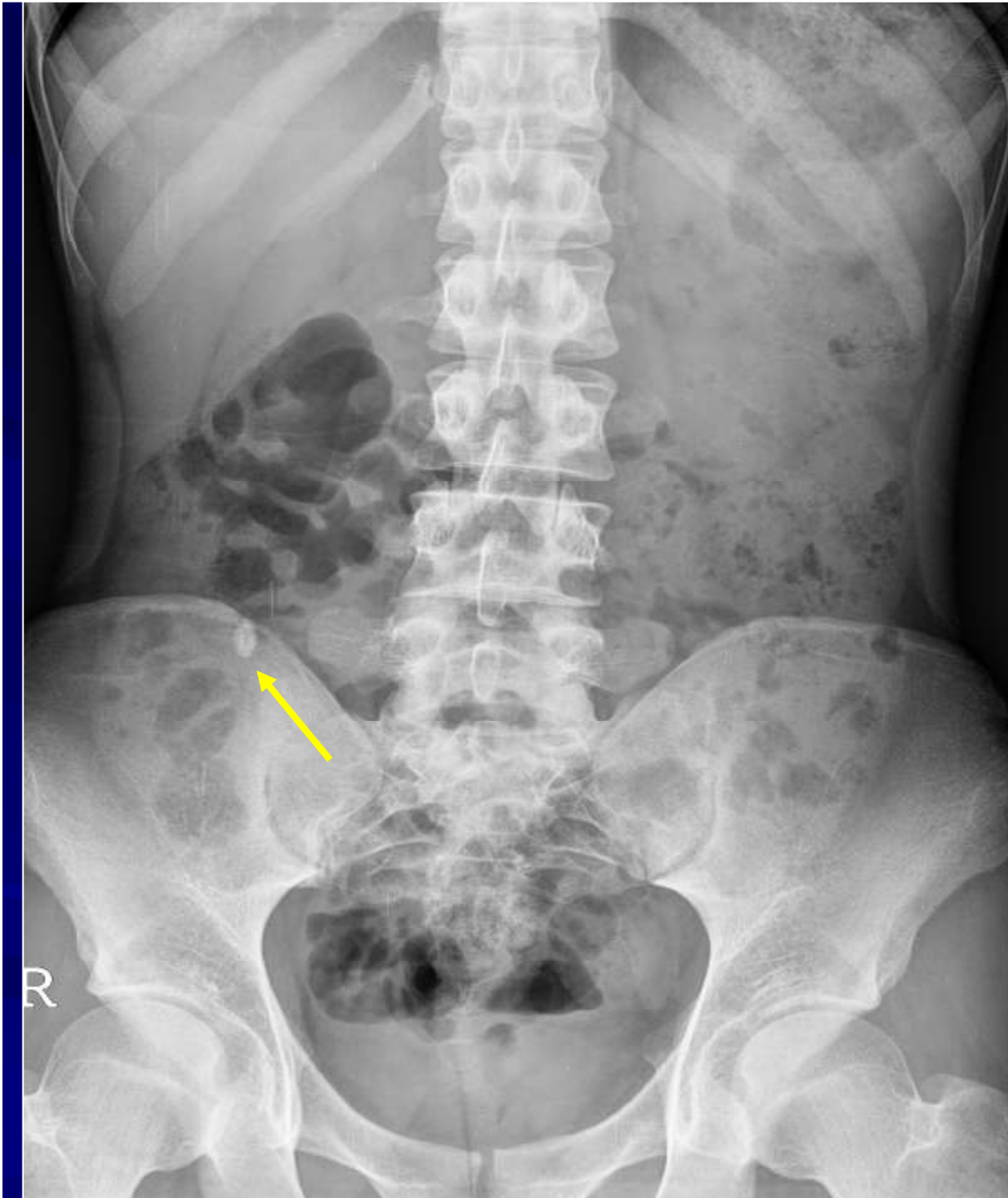



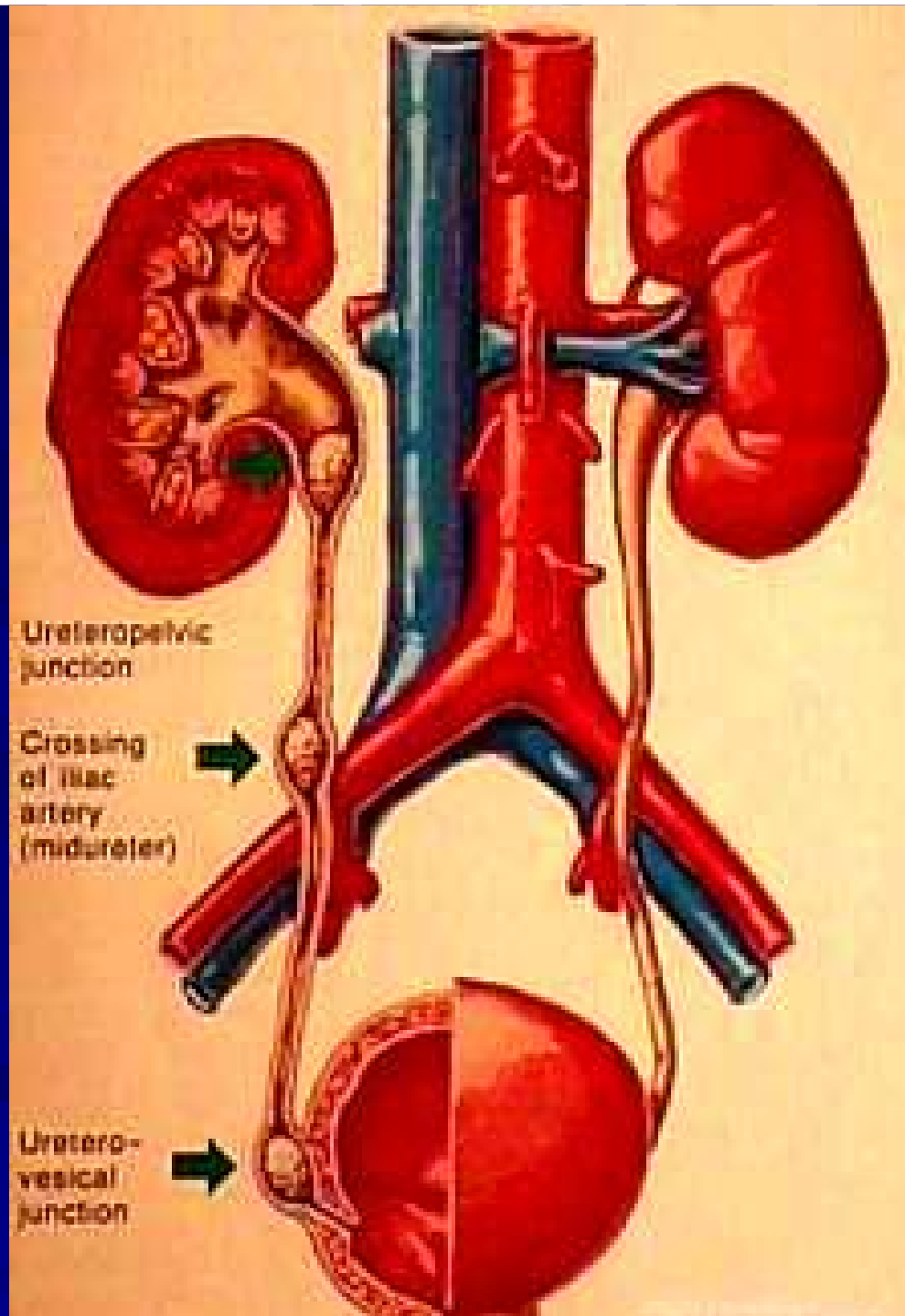
小心，膽結石掉下來就是總  
膽管結石

# 膽結石、總膽管結石

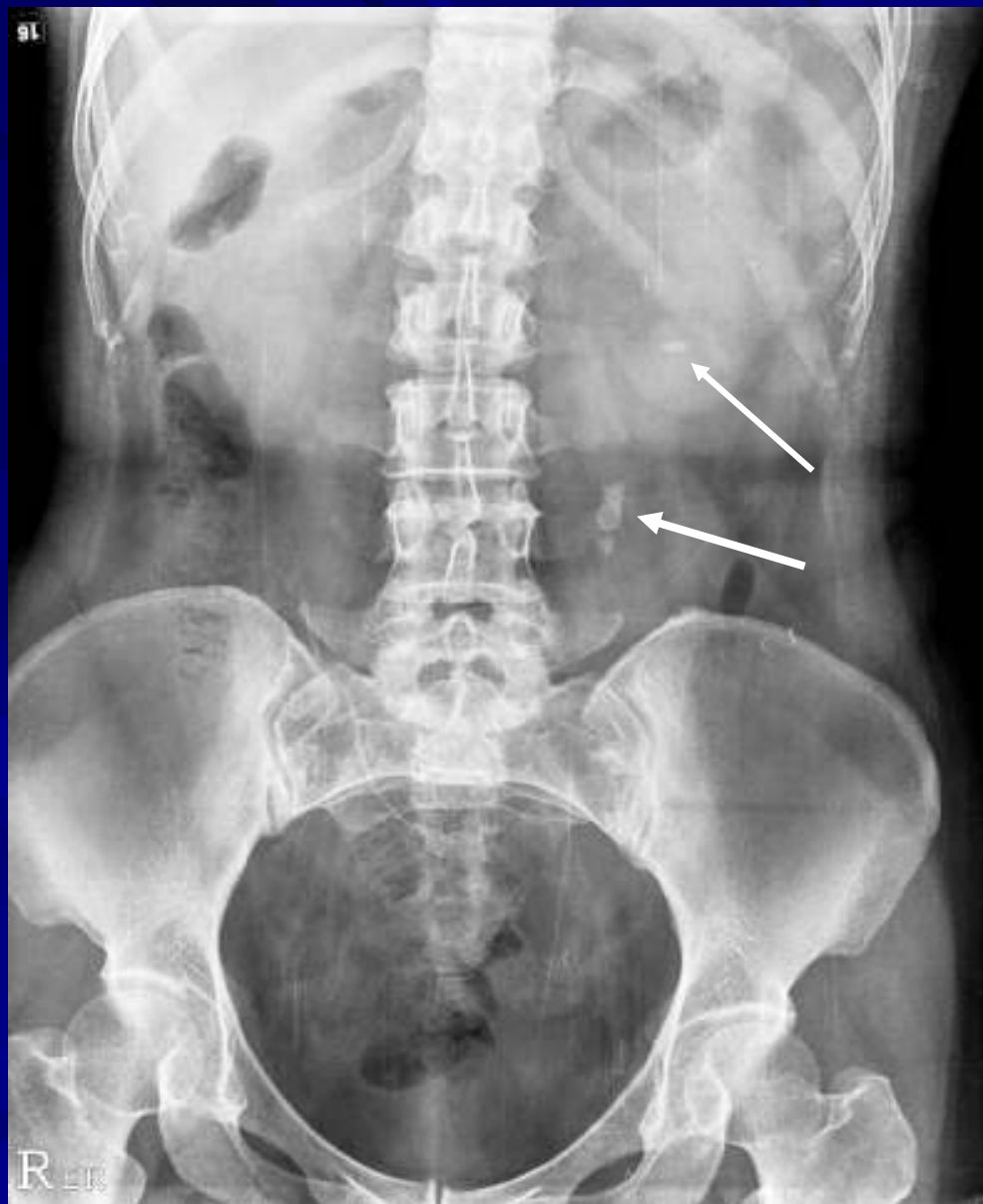



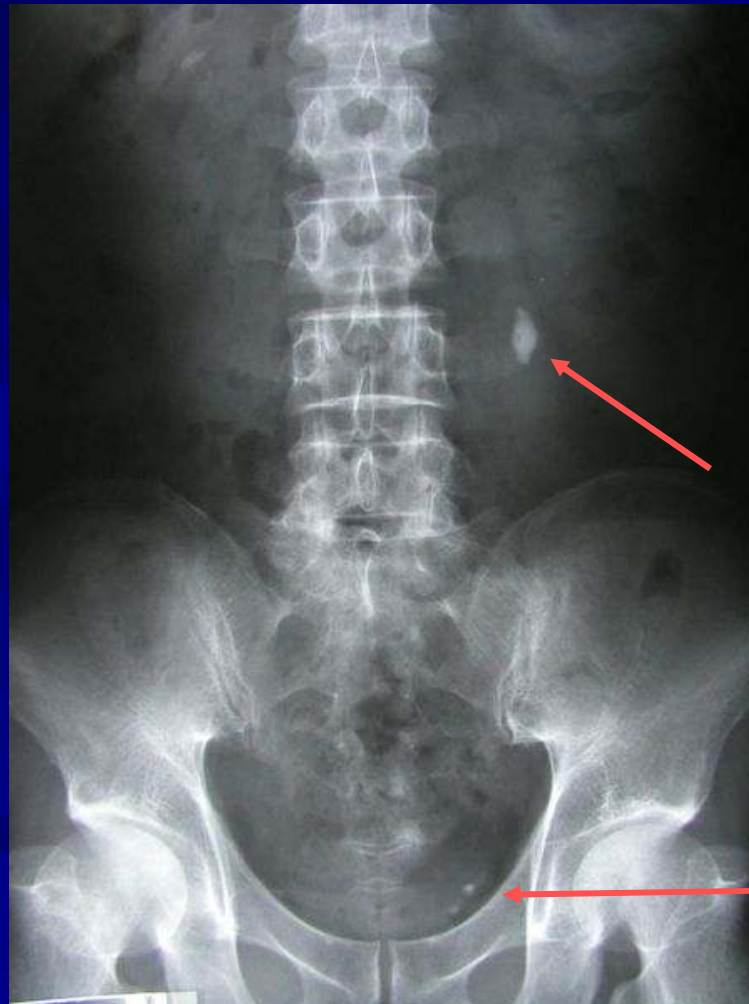# Appendicolith 糞石



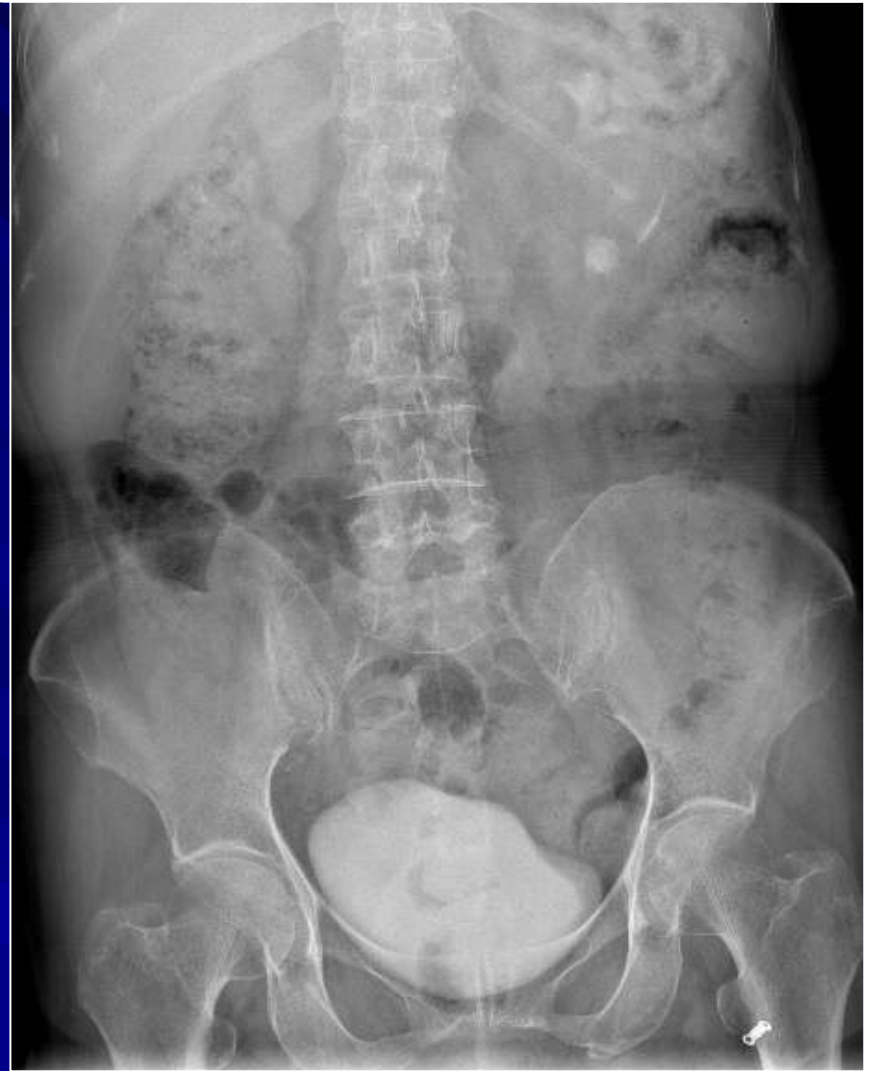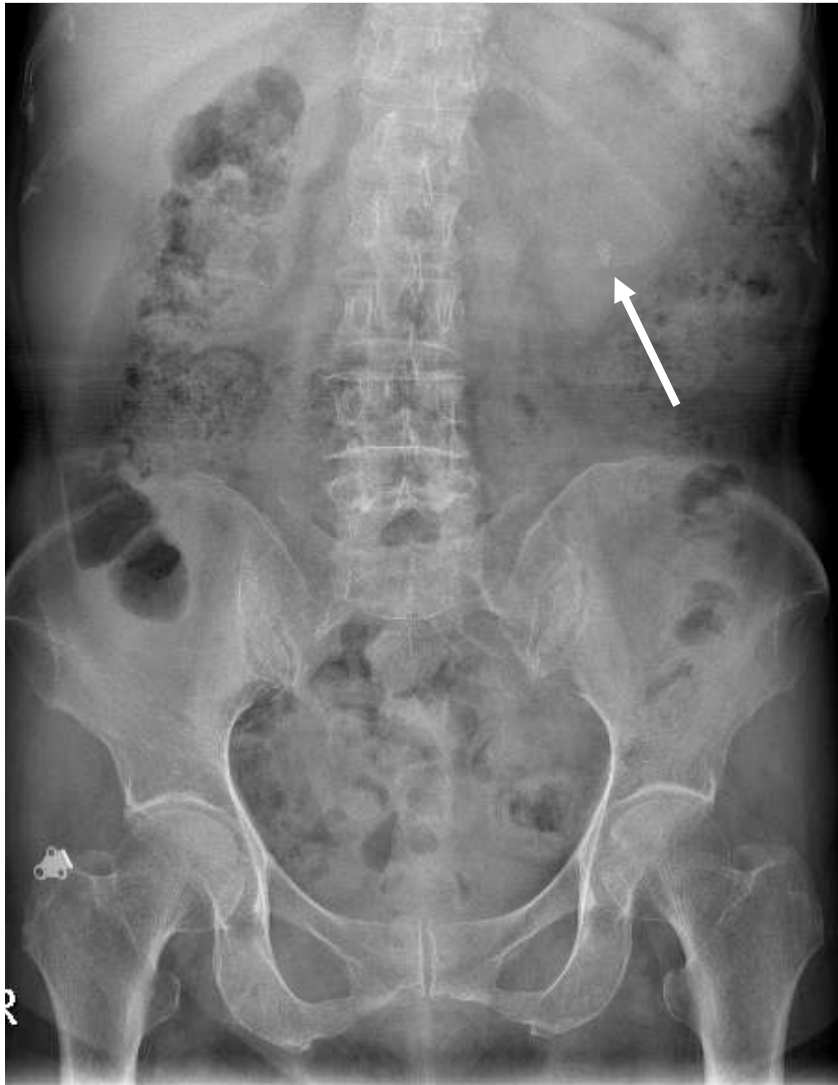# 腎結石 輸尿管結石



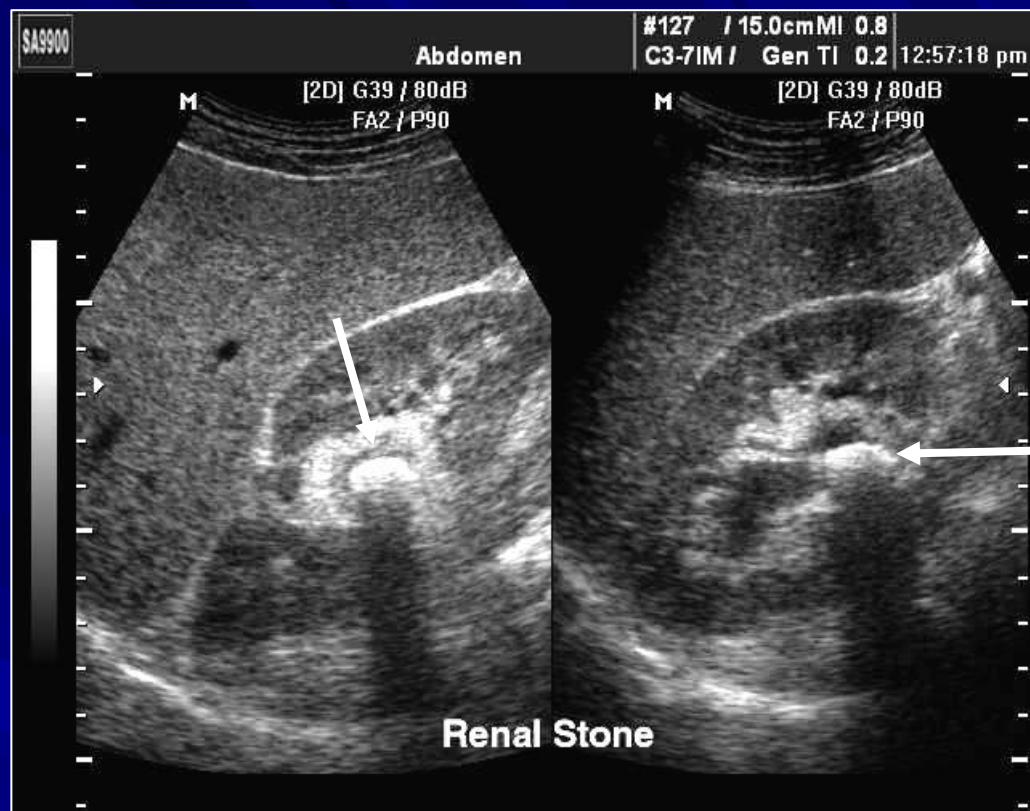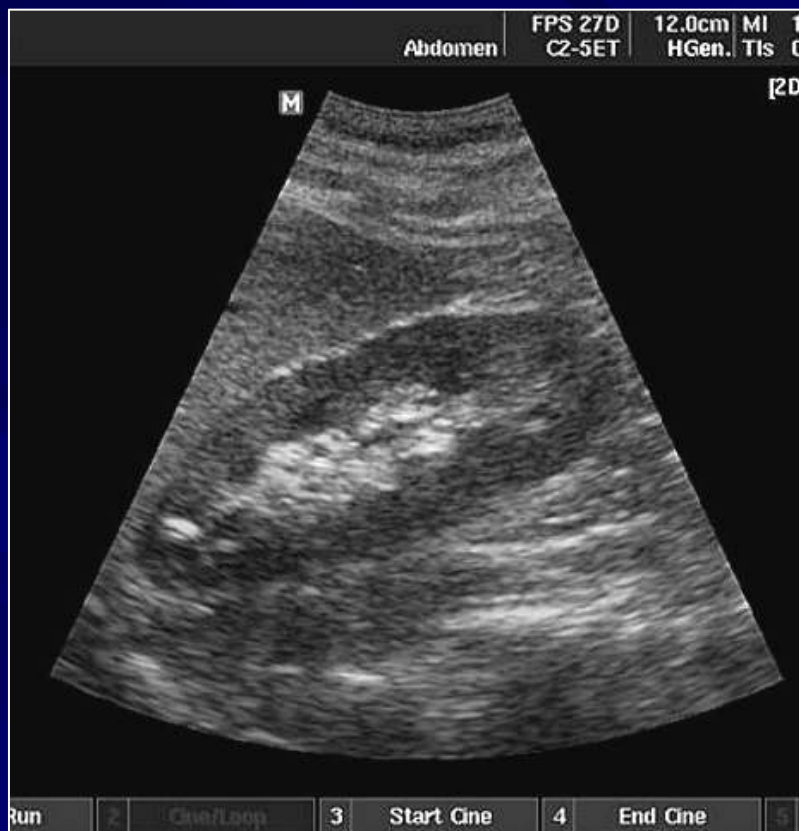# 輸尿管結石



phlebolith

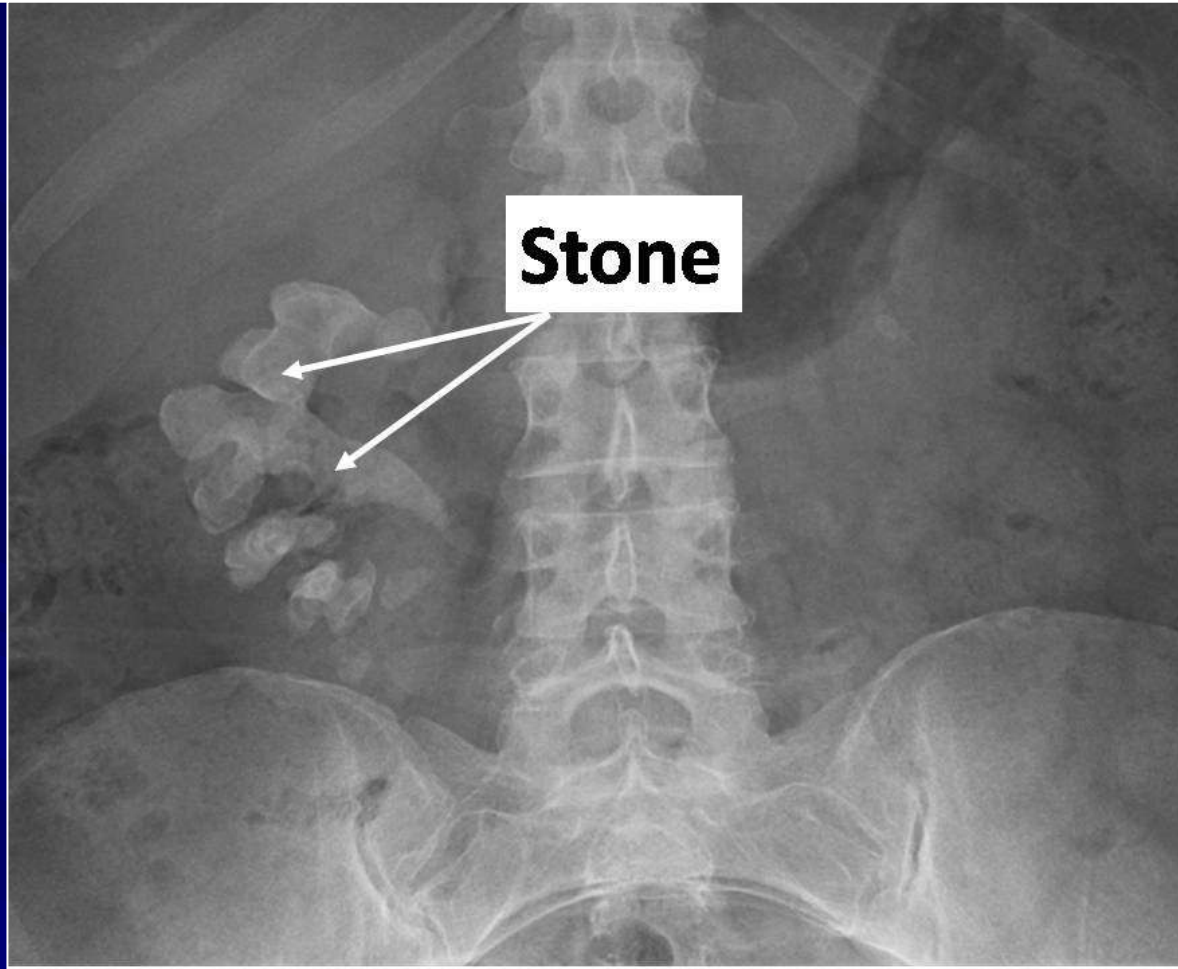


左：腎結石  
右：IVP



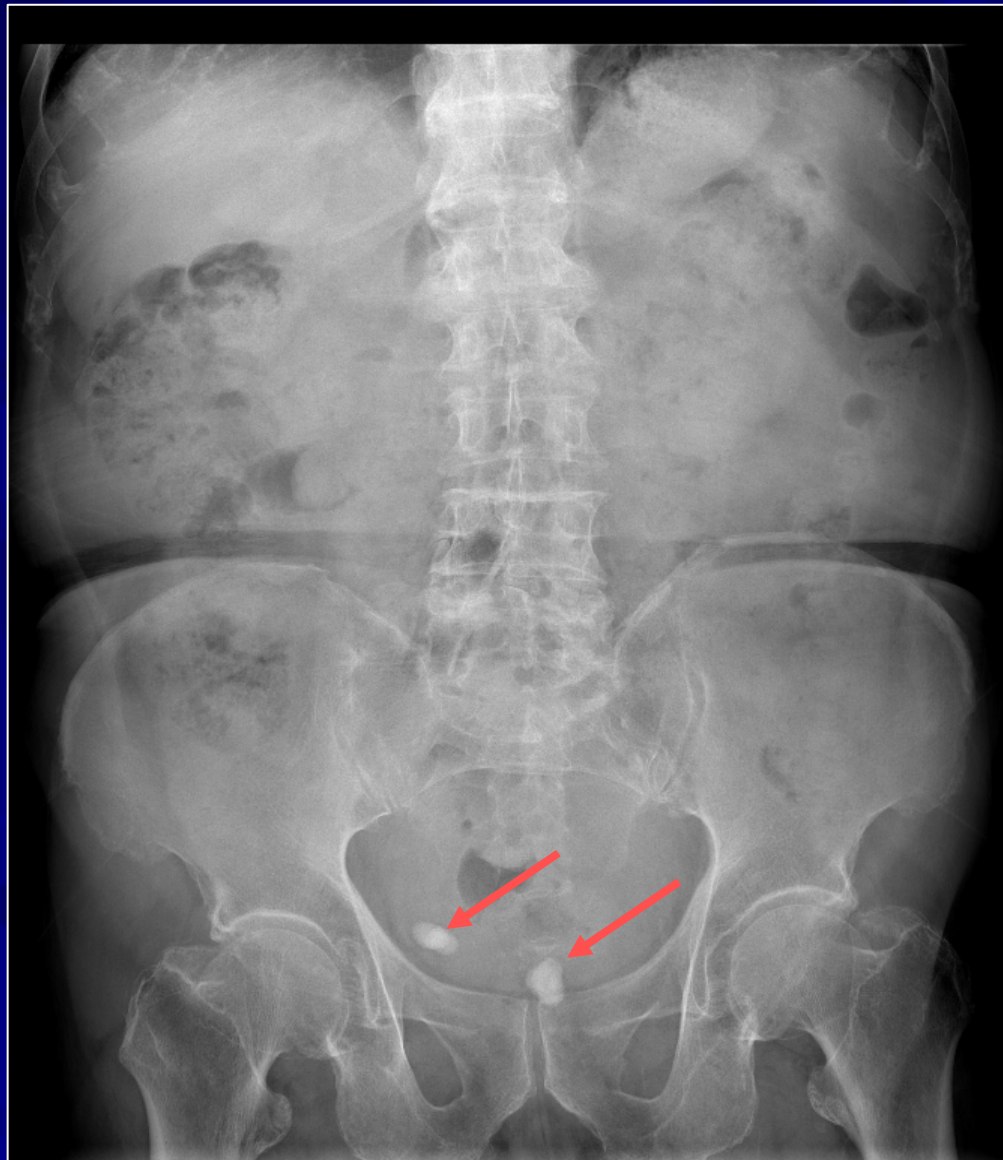左：正常  
右：腎結石、水腎



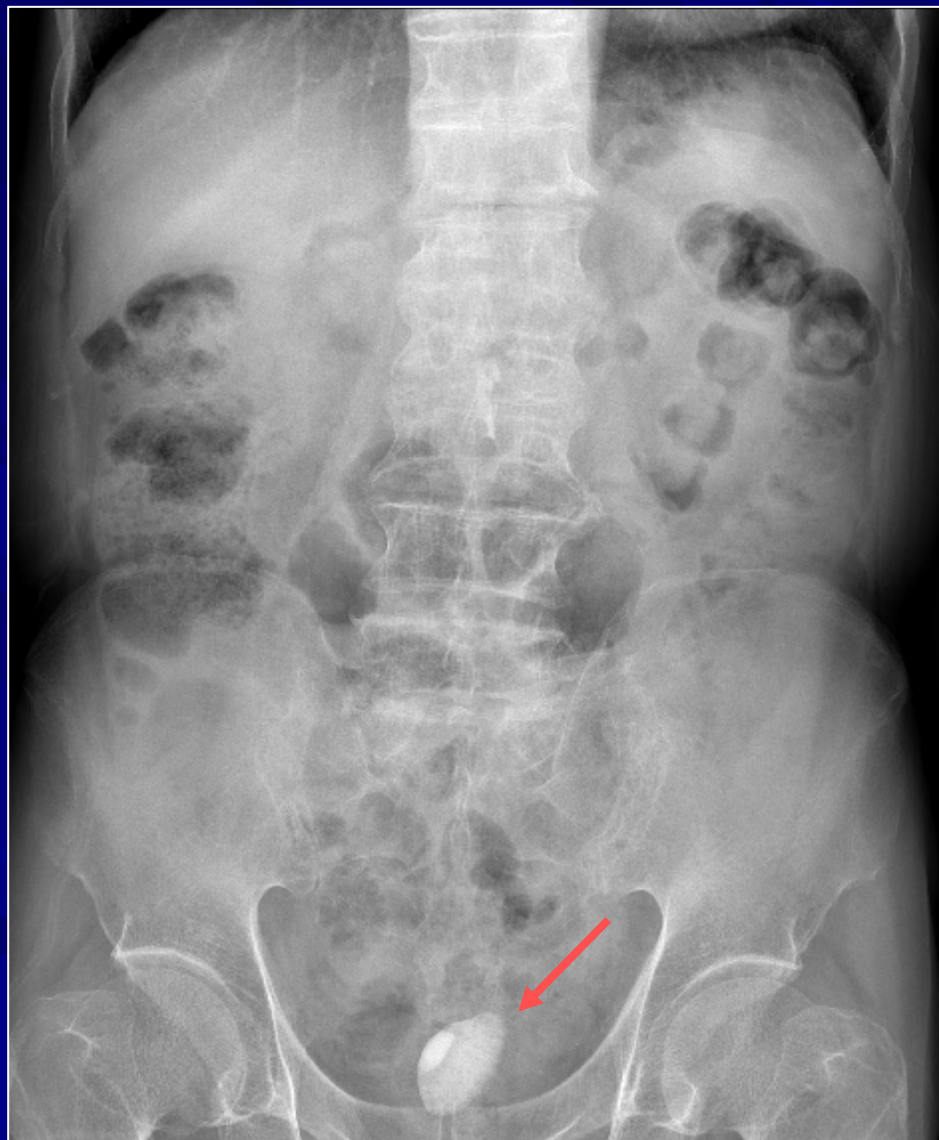


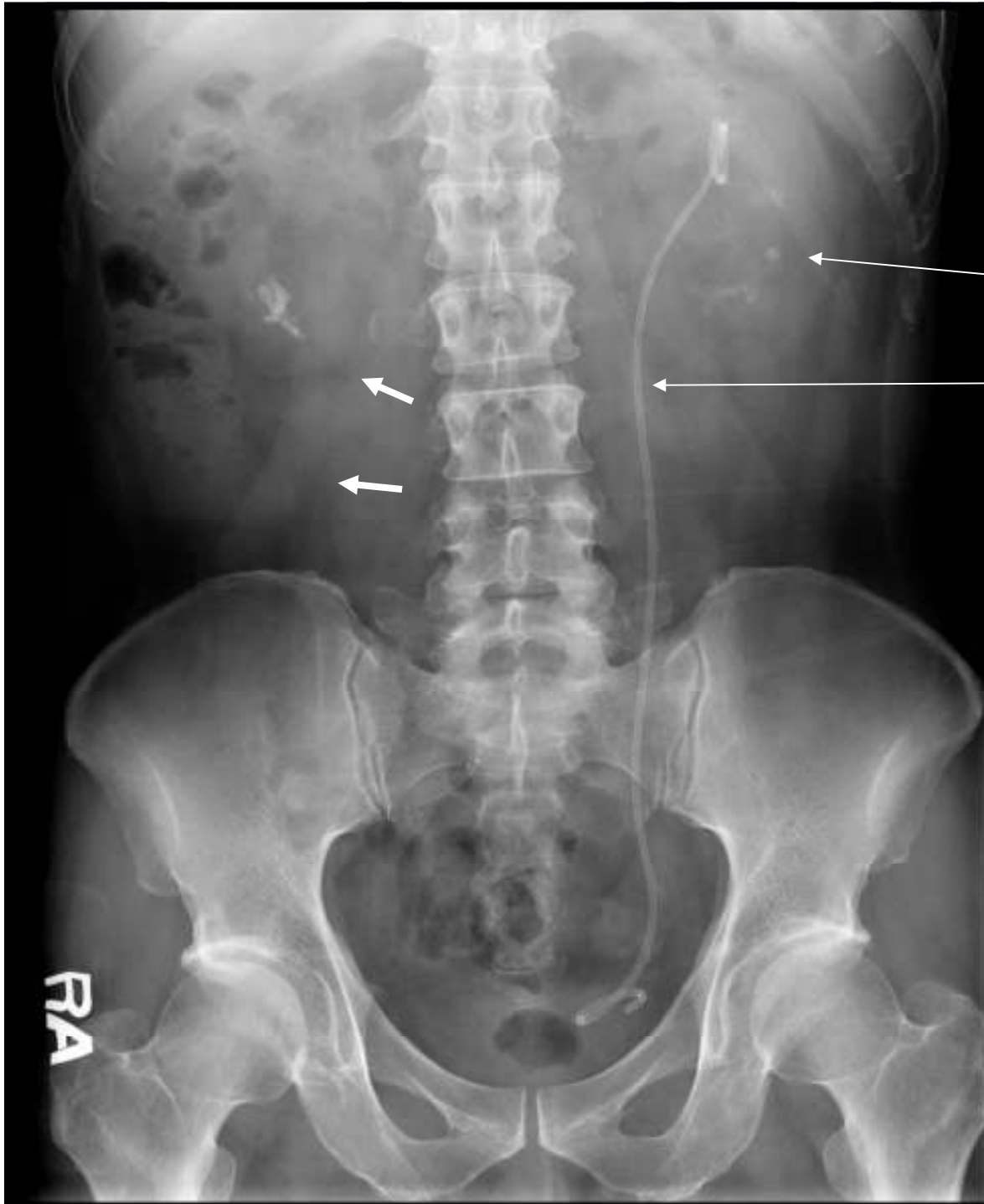# 鹿角石

# 膀胱結石

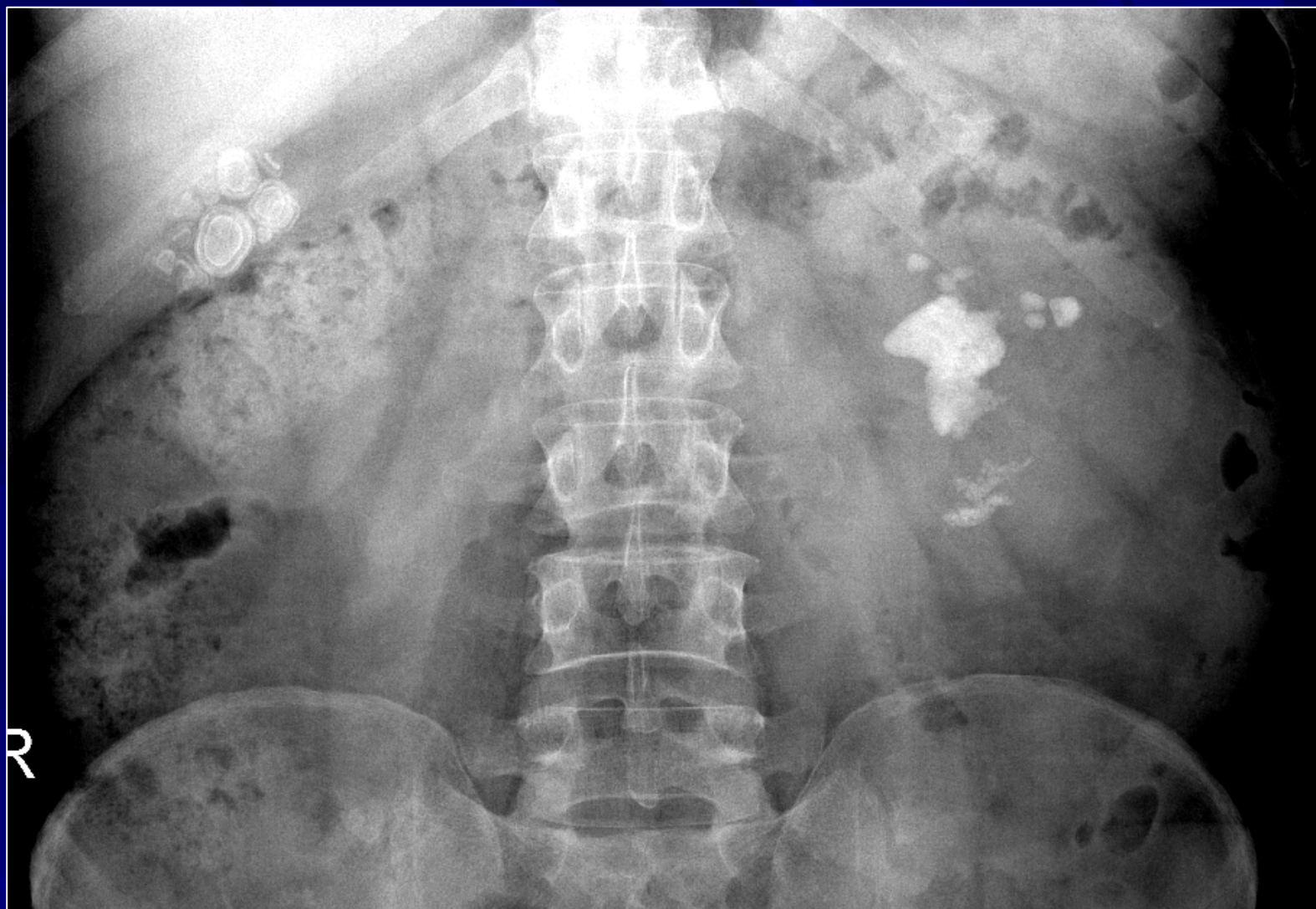


# 好大的膀胱結石

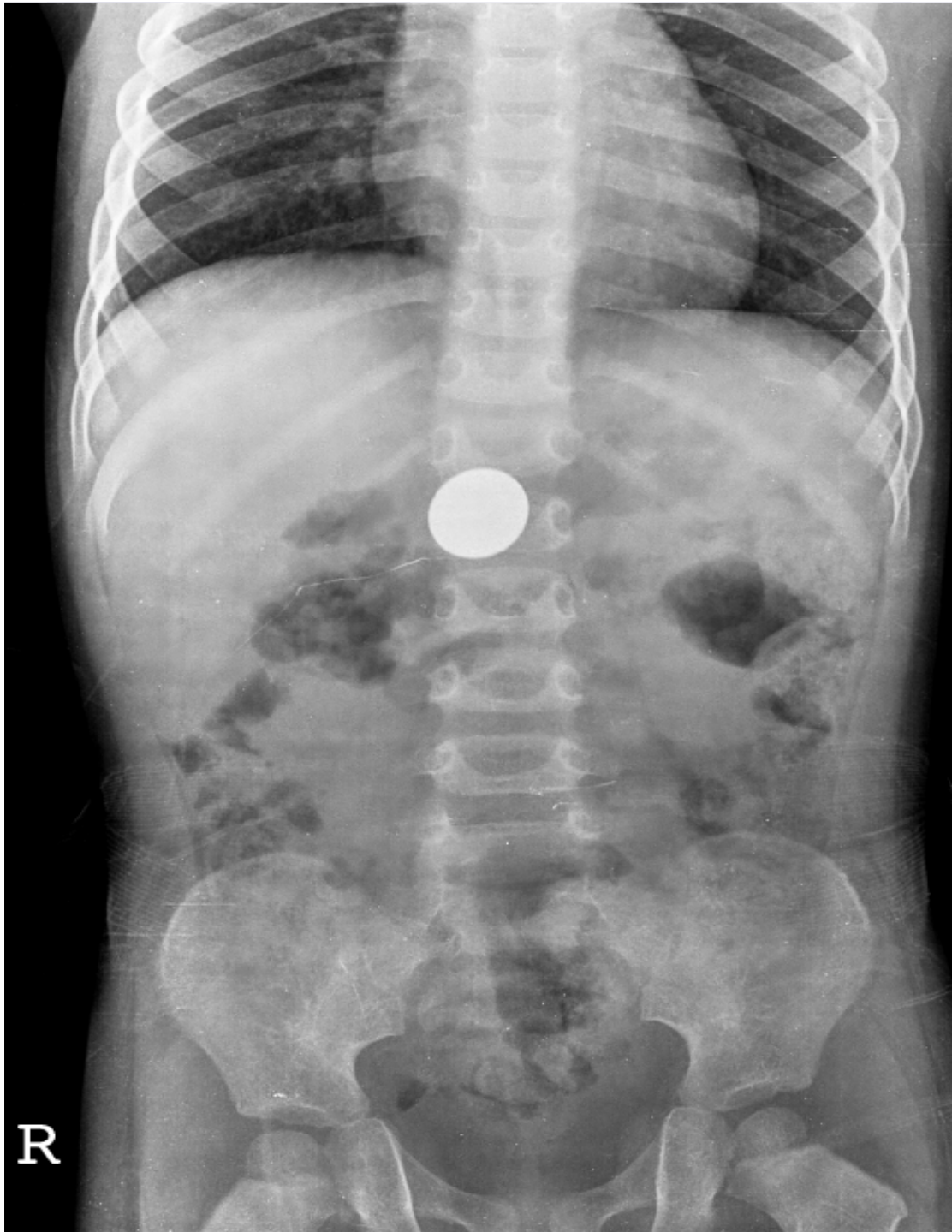



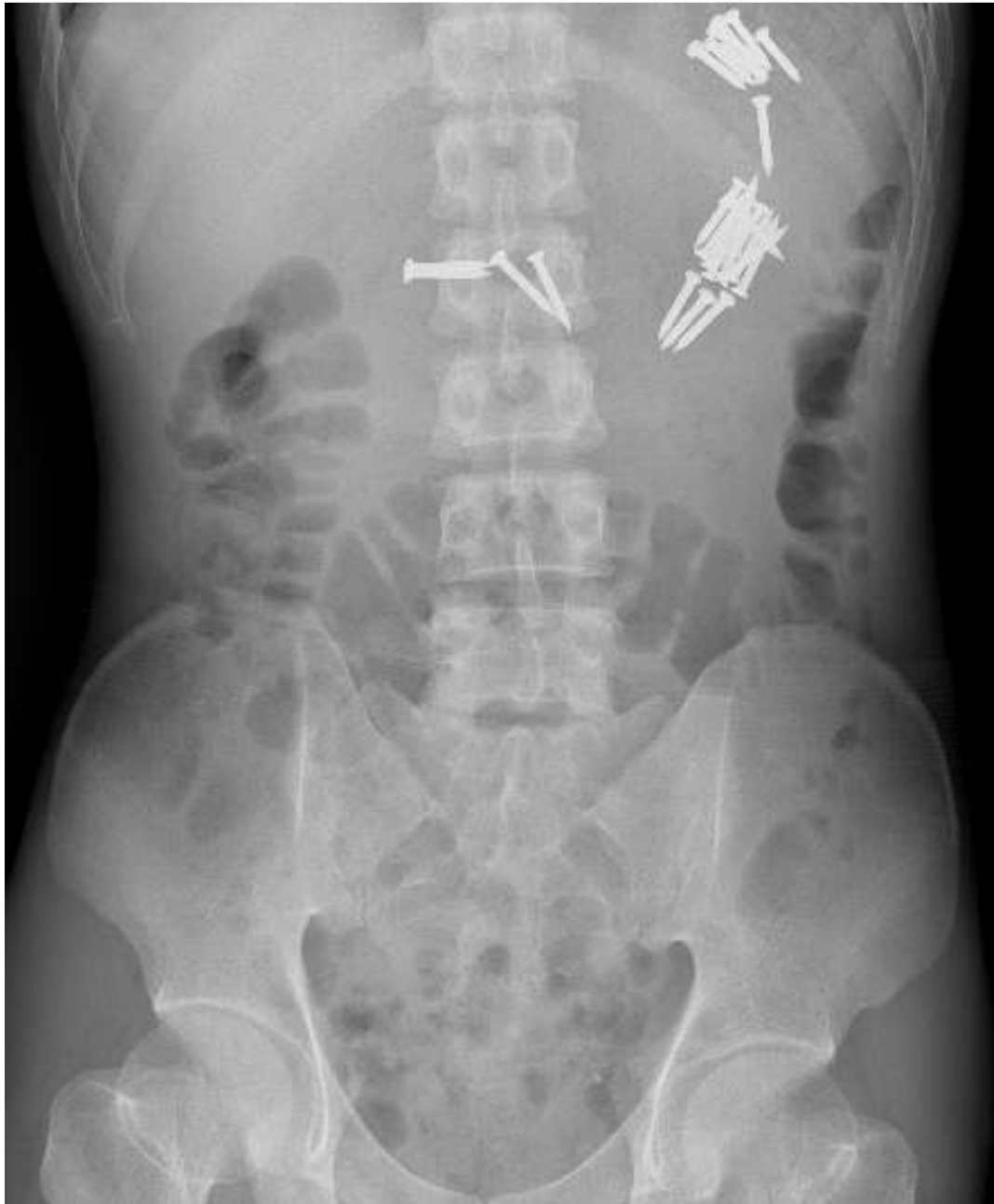
Psoas muscle line



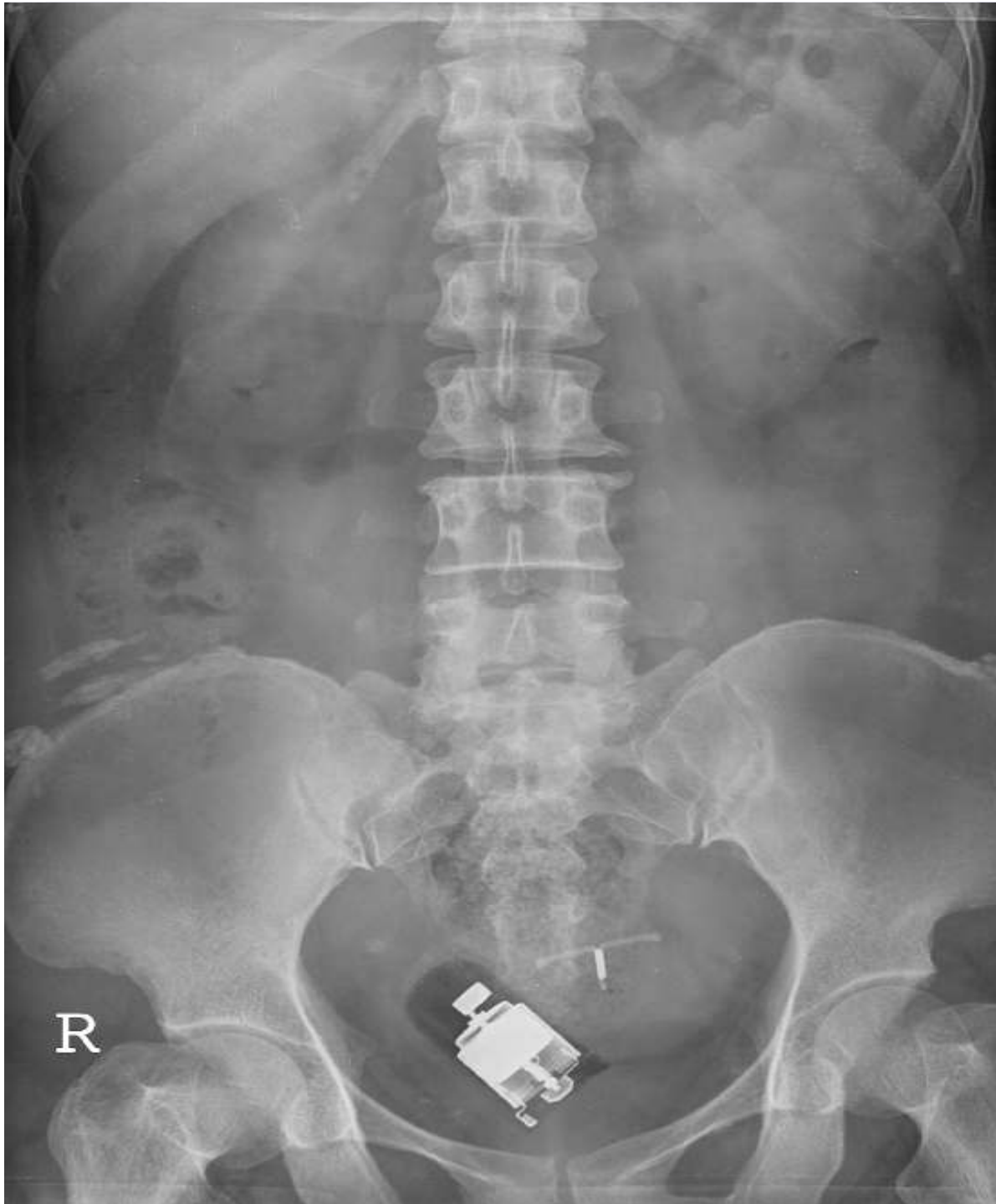
比比看膽結石和腎結石的不同



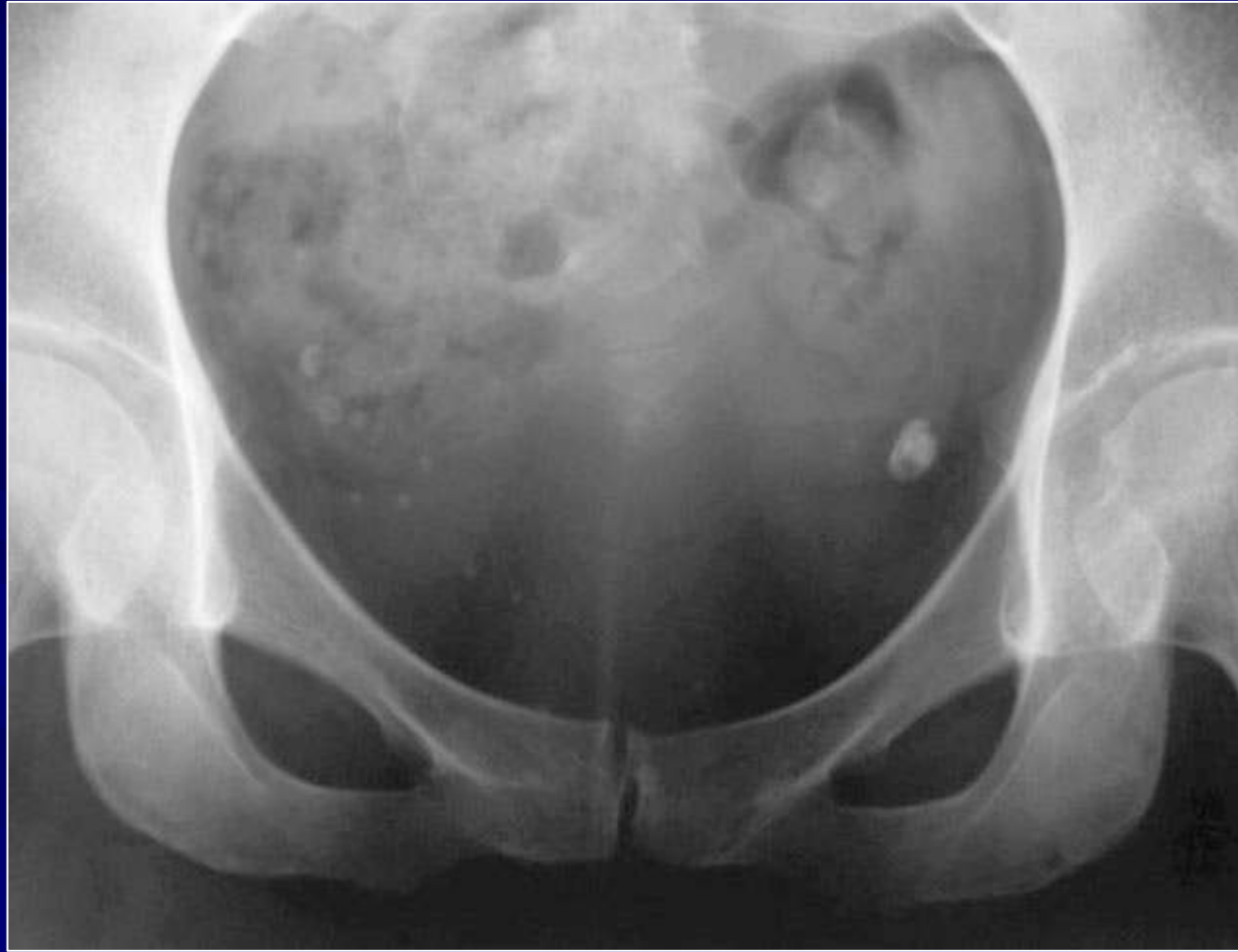# 儲蓄致富



## 特異功能

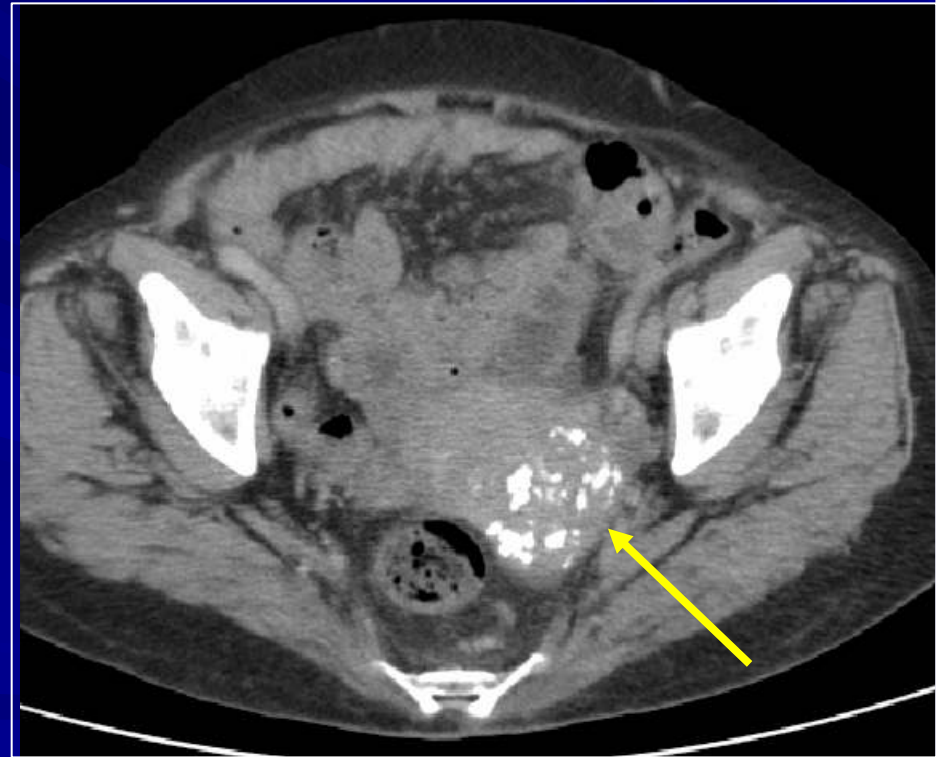
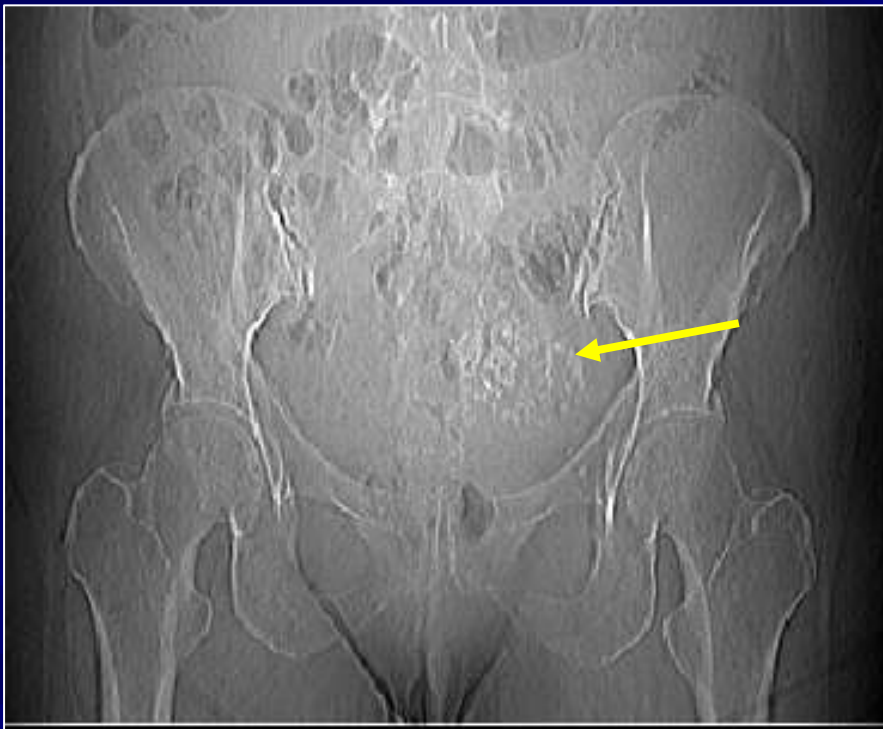


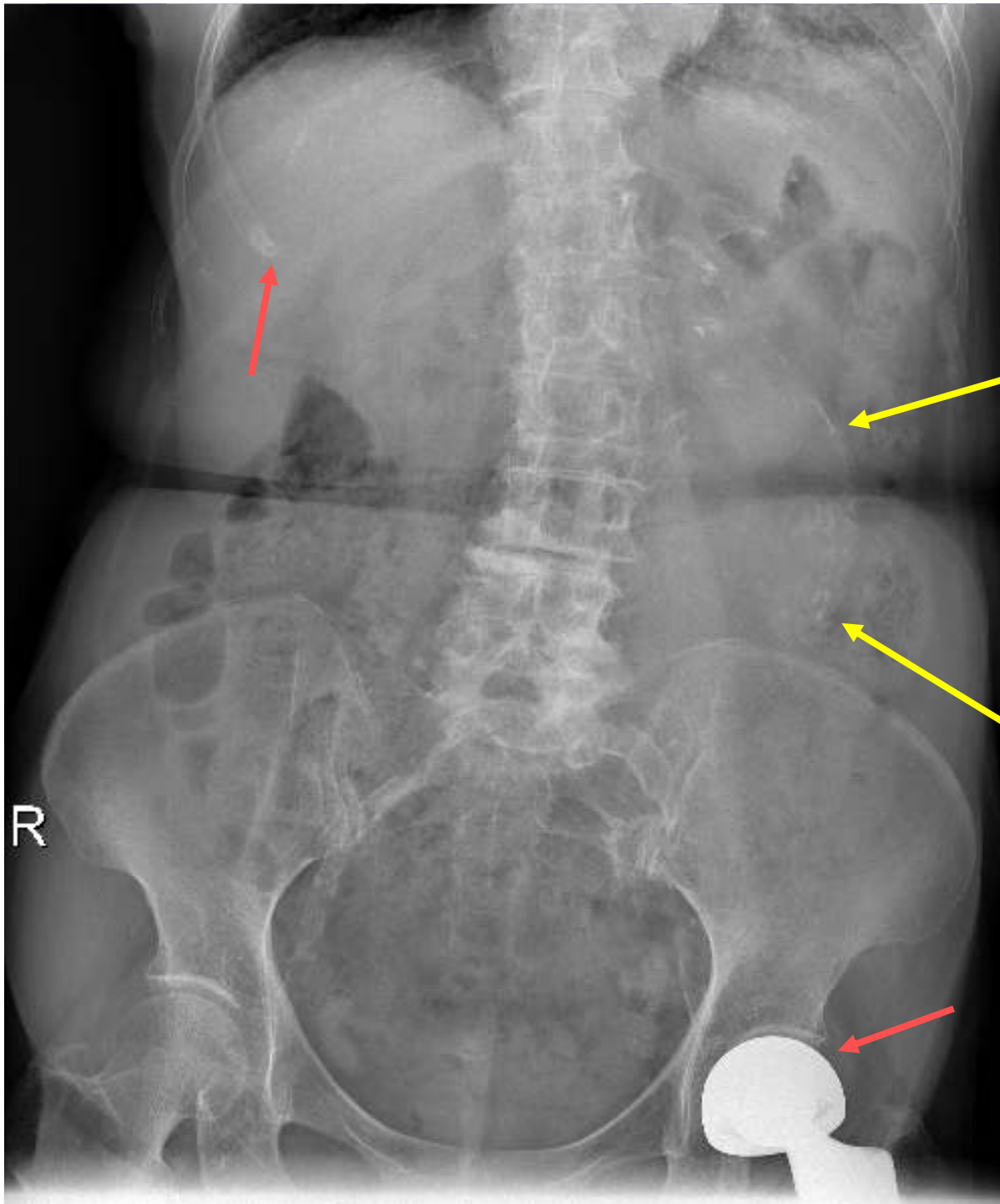
也是特異  
功能



Phlebolith : 靜脈石

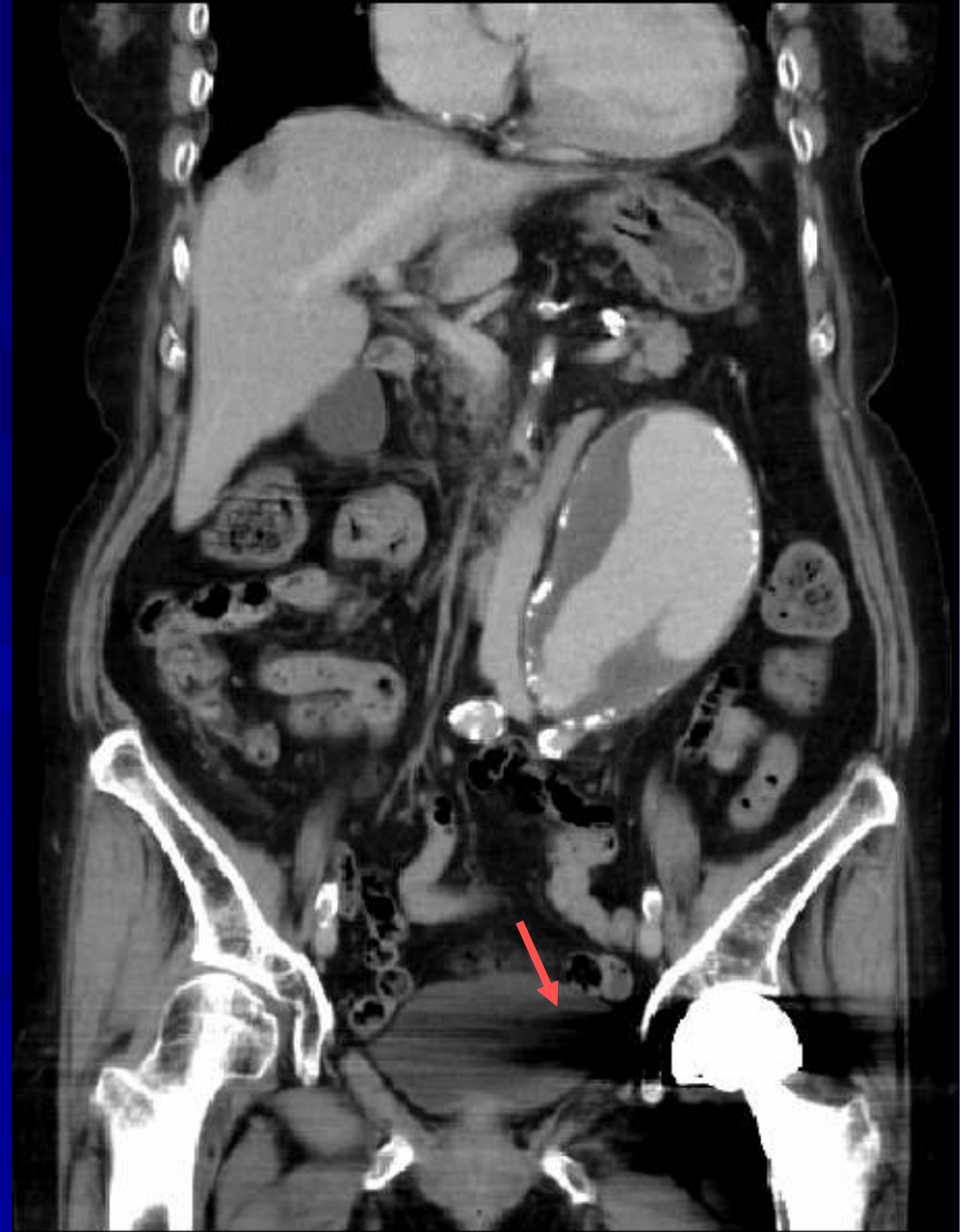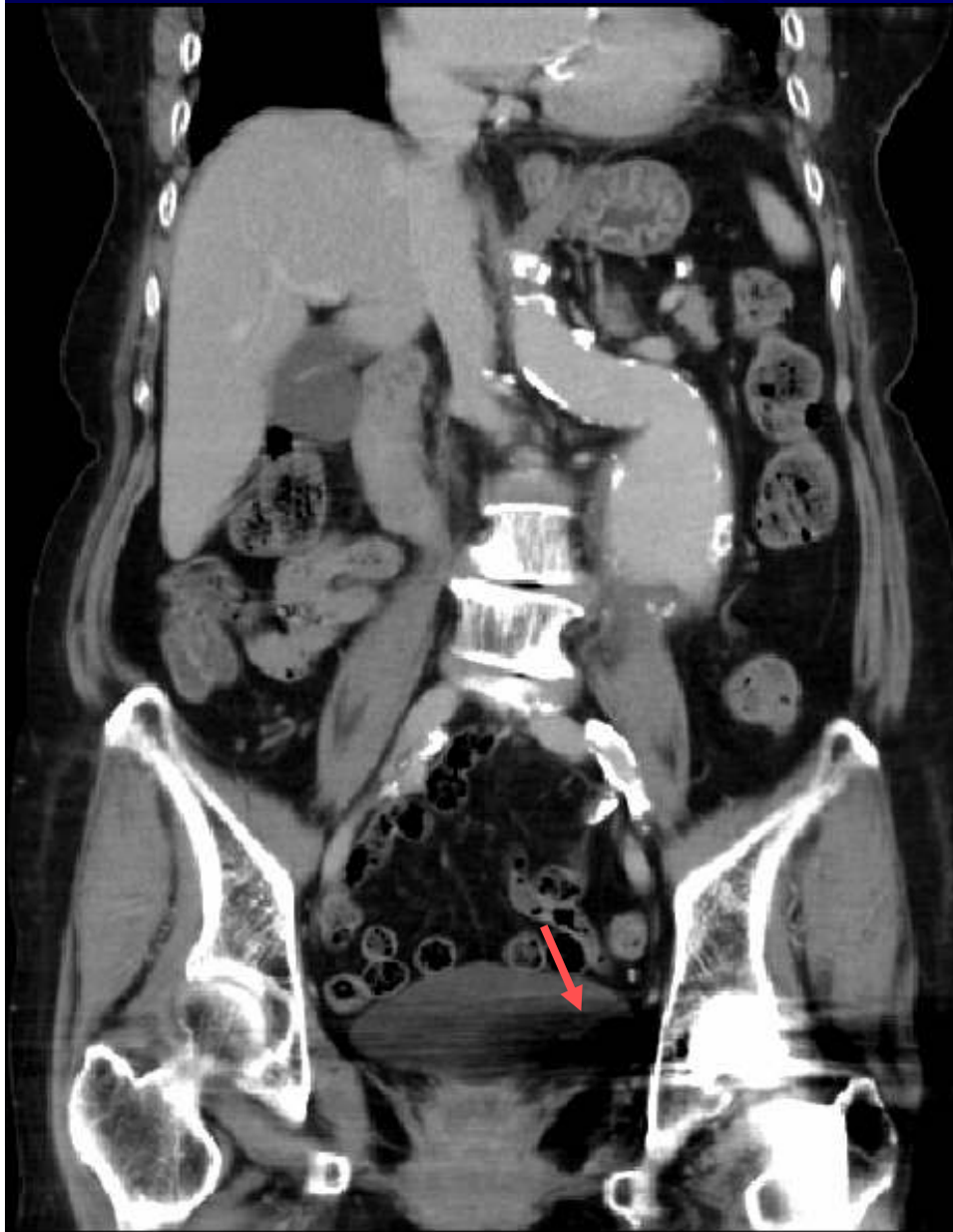# 子宮肌瘤鈣化





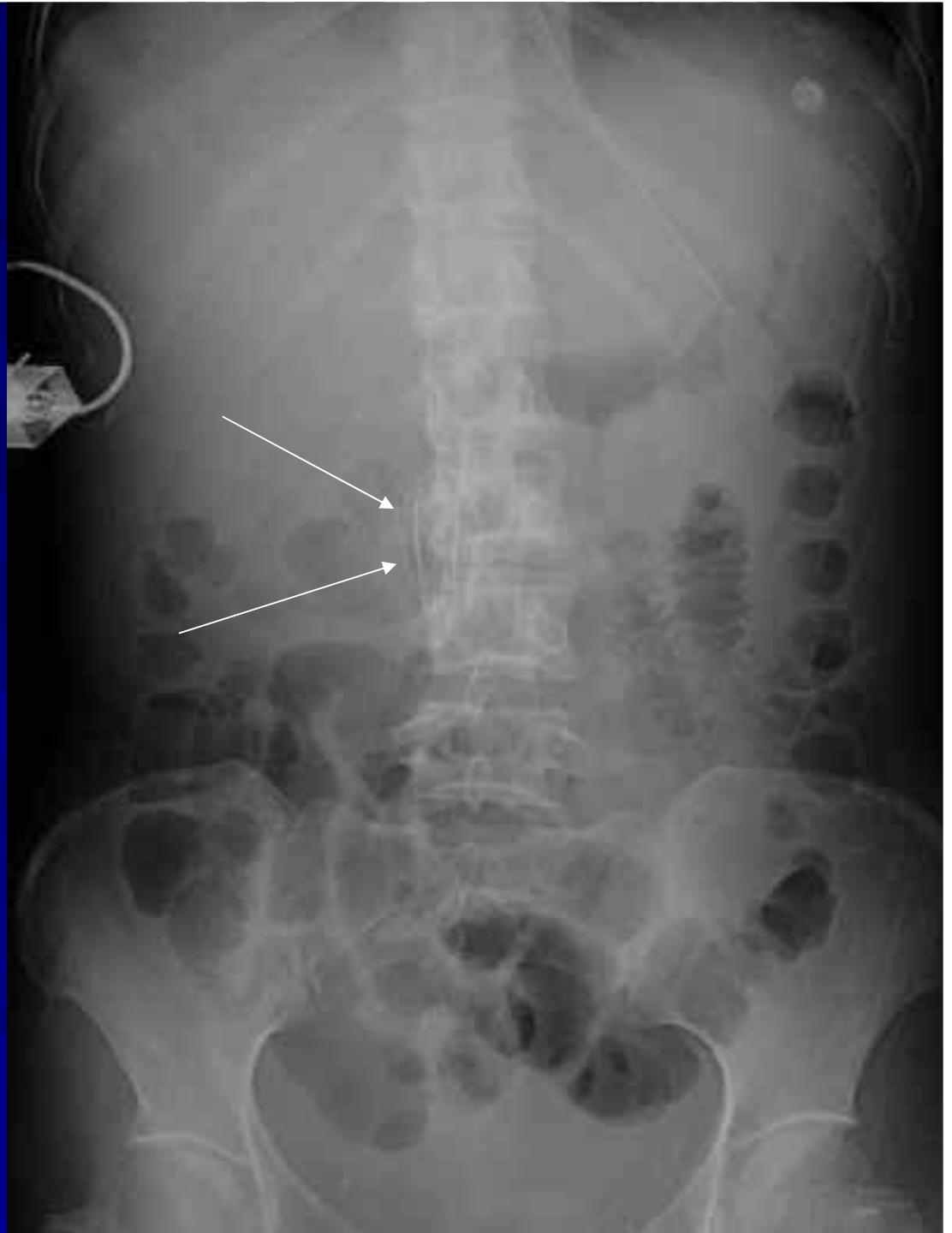What are these?


# 主動脈動脈瘤及鈣化



■ What's this?

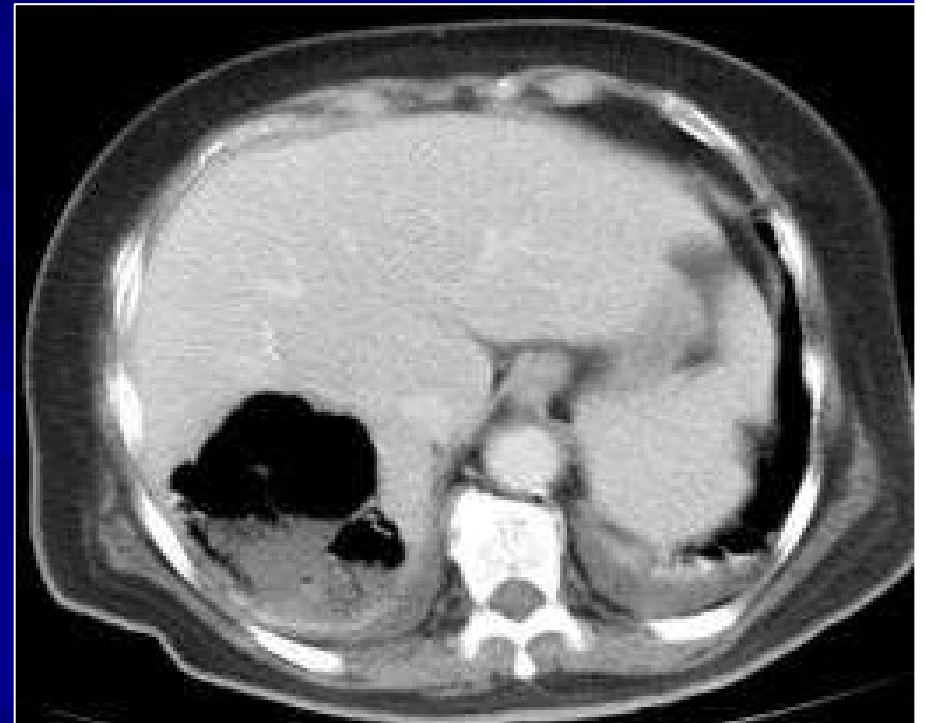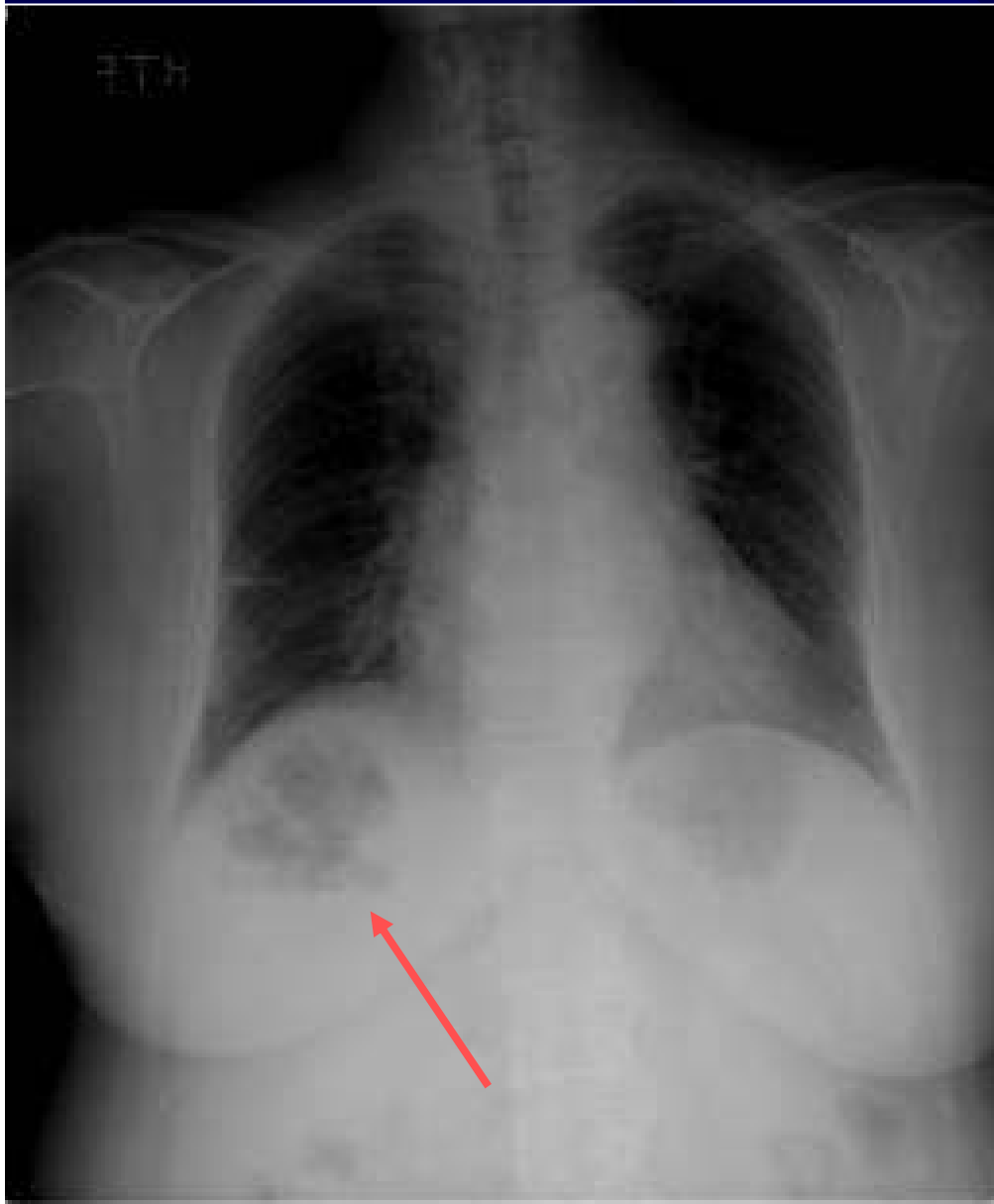
■ (有點難)



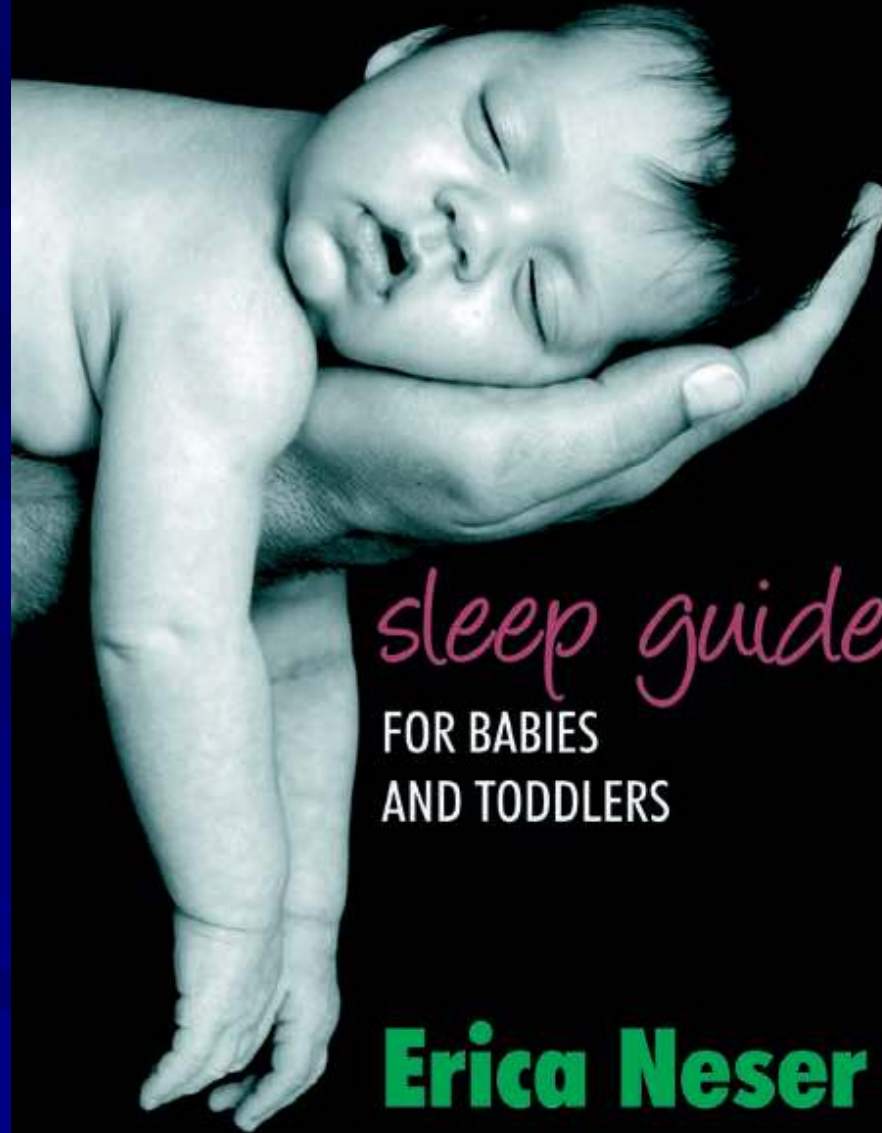


■ IVC filter

# 肝膿瘍



A BABY-FRIENDLY WAY TO ESTABLISH GOOD SLEEPING HABITS



*sleep guide*

FOR BABIES  
AND TODDLERS

**Erica Nesor**